




Surgical Planning Laboratory
Brigham and Women's Hospital
Boston, Massachusetts USA

a teaching affiliate of
Harvard Medical School

3D VISUALIZATION OF DICOM IMAGES FOR RADIOLOGICAL APPLICATIONS

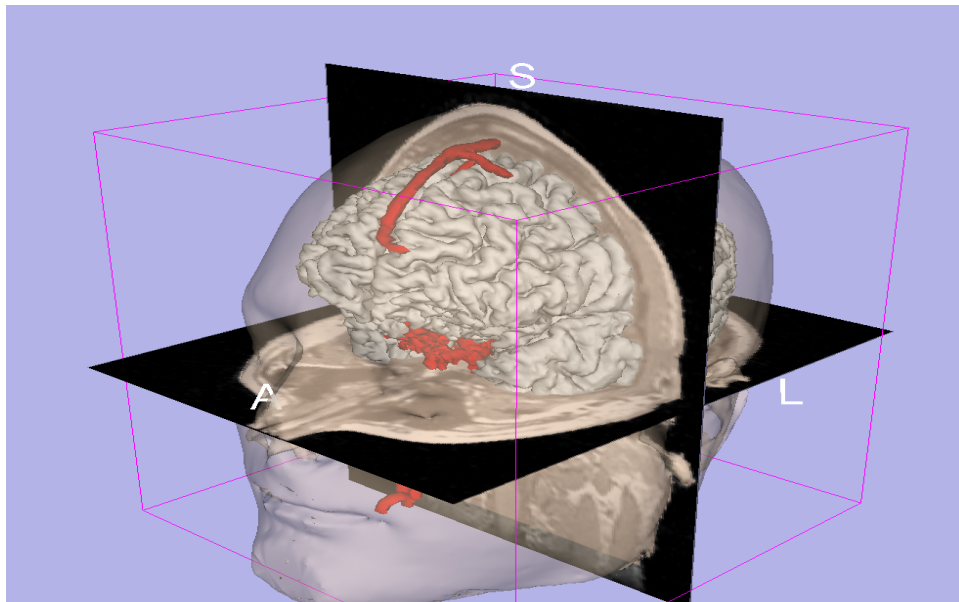
Sonia Pujol, Ph.D., Harvard Medical School
Director of Training, National Alliance for Medical Image Computing

Kitt Shaffer, M.D., Boston University
Vice-Chairman for Education, Boston University School of Medicine





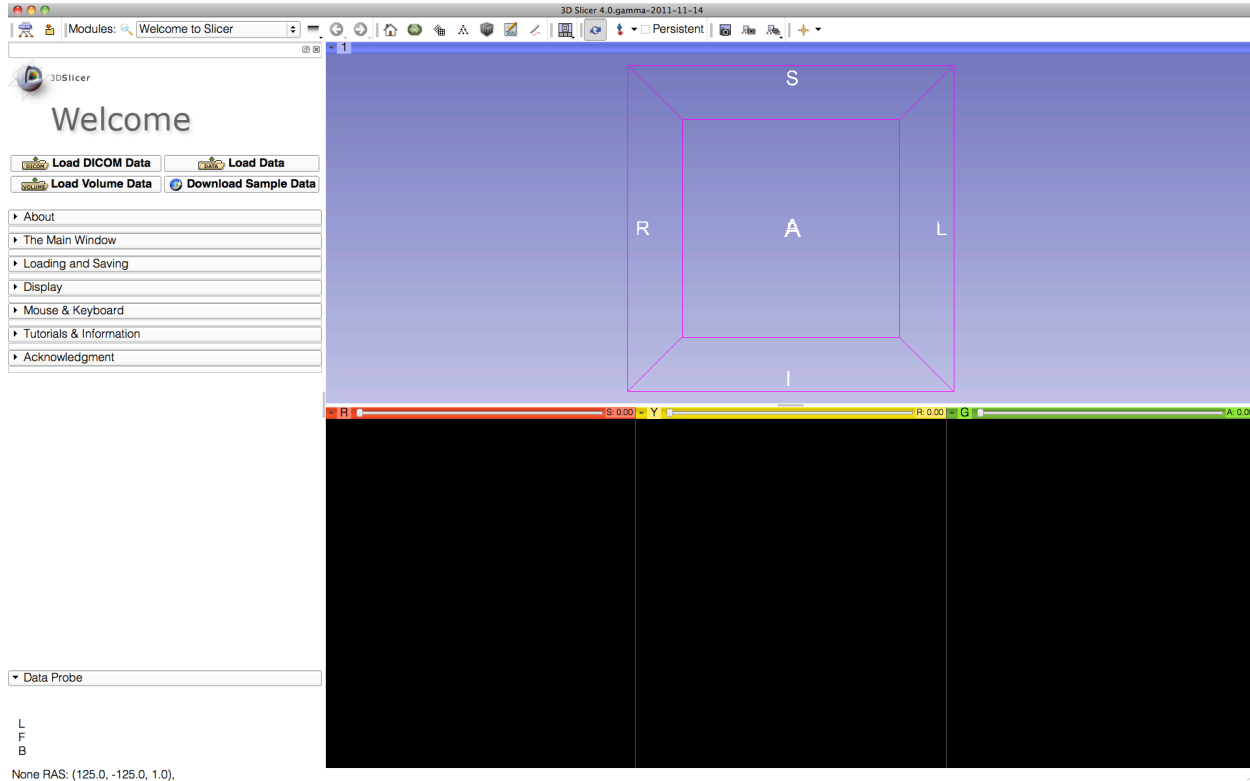
Goal



- The Goal of this tutorial is to guide you through the process of 3D data loading and visualization of DICOM data and surface-models



Slicer4



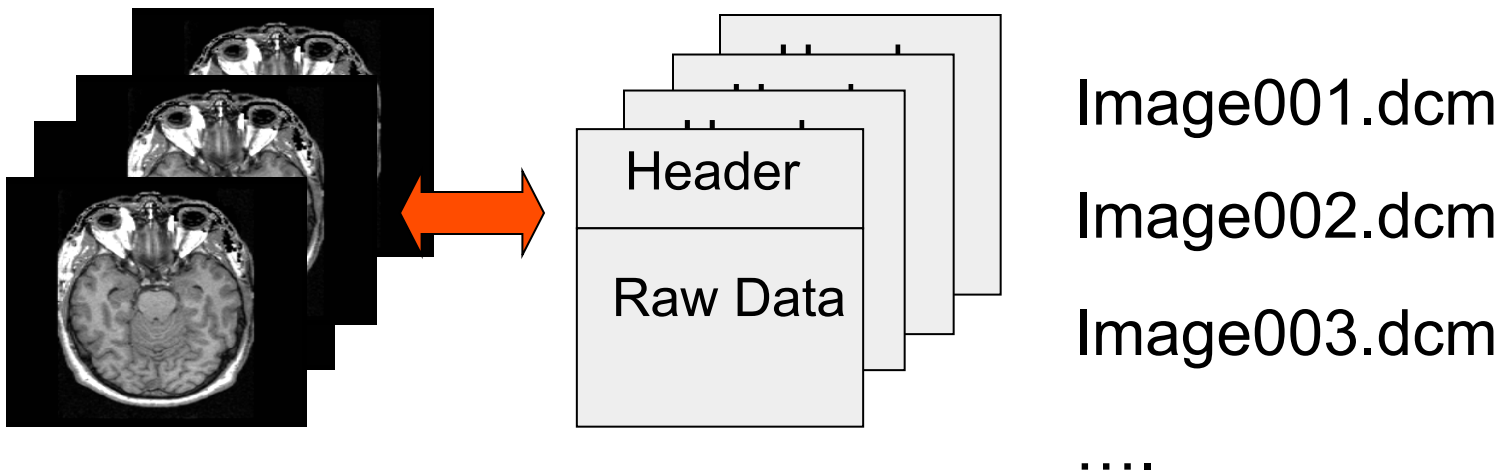


PART 1: LOADING A DICOM VOLUME



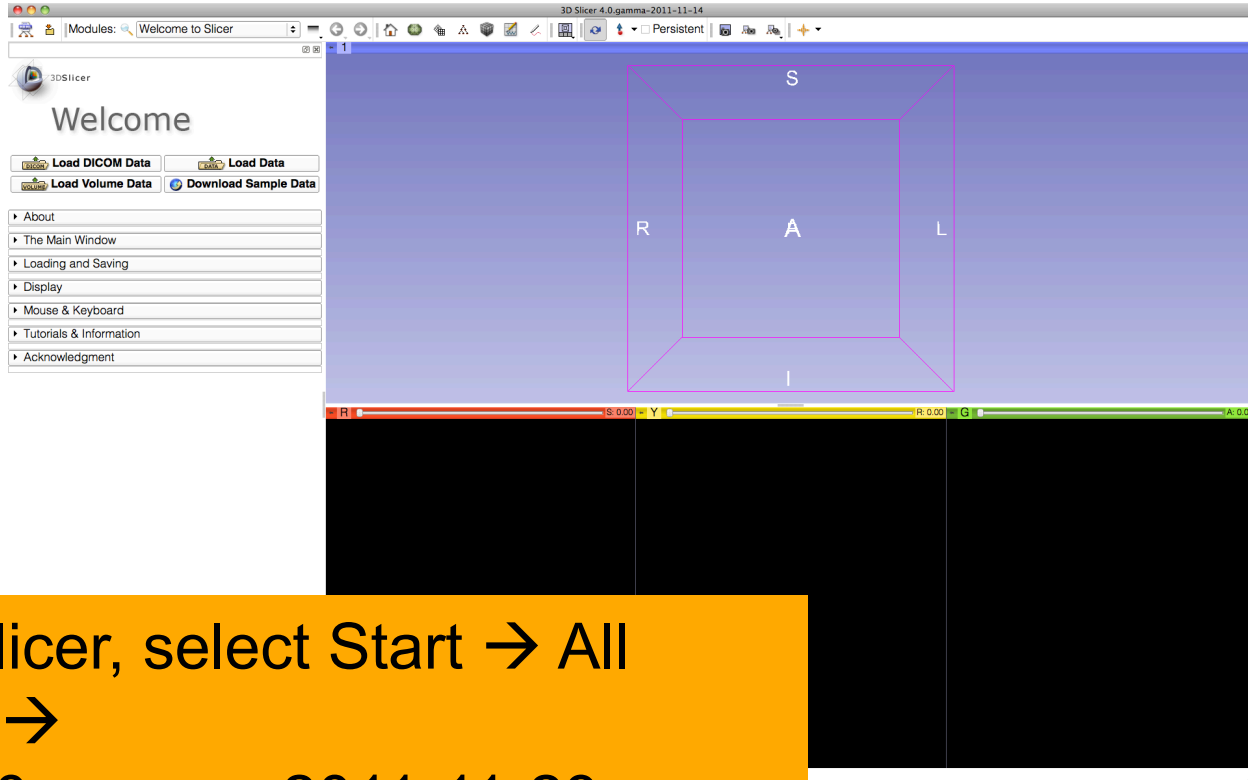
The DICOM 3.0 File Format

Radiological imaging equipment produce images in DICOM file format ('.dcm files')





Slicer4



To start Slicer, select Start → All Programs → Slicer4-4.0.gamma-2011-11-23

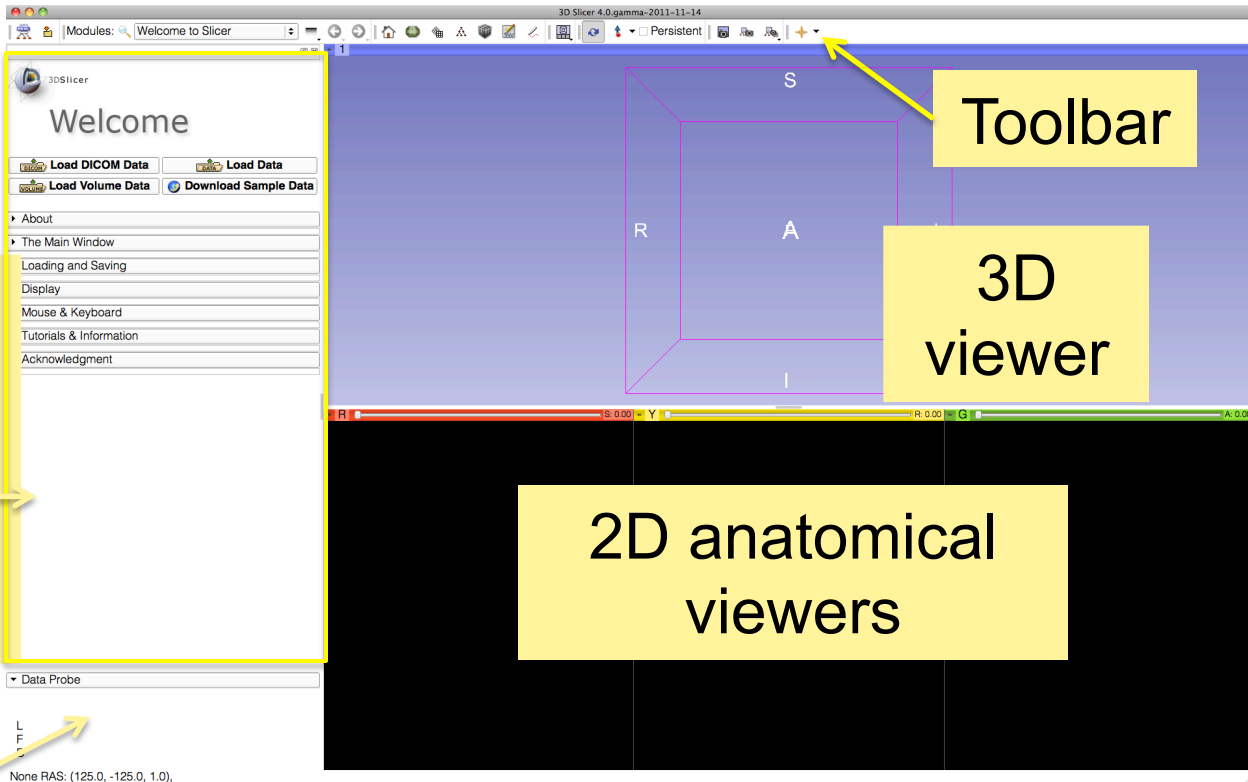


Slicer User Interface

Main Menu

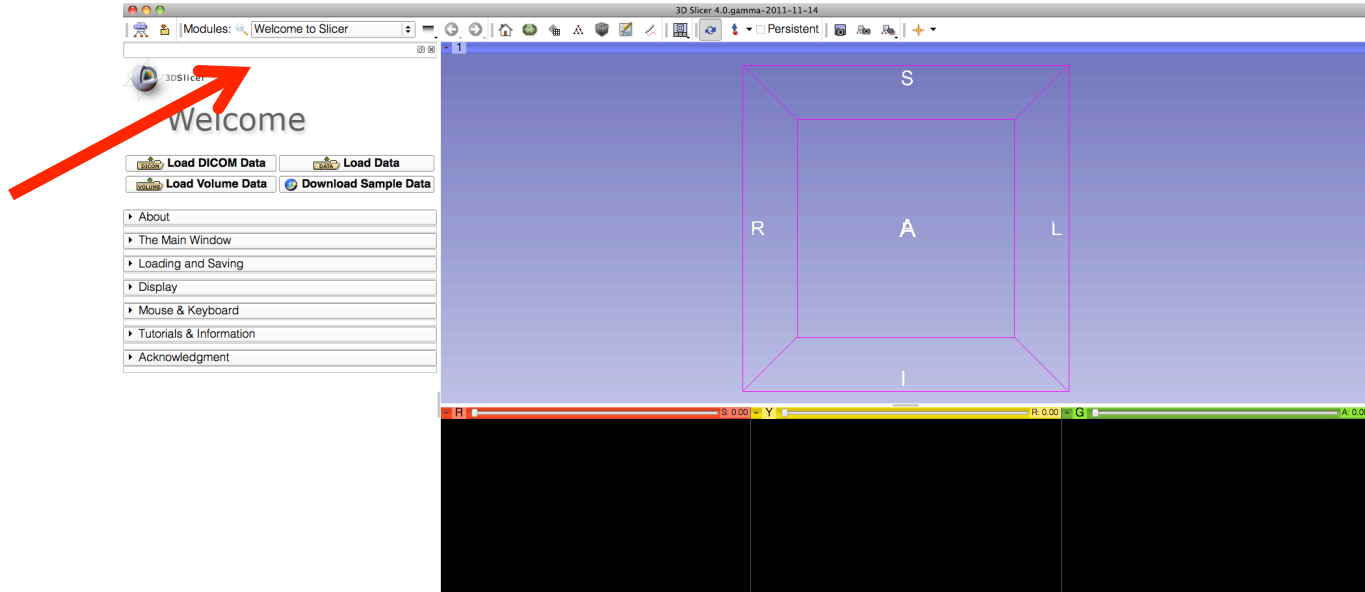
GUI panel of the Slicer Welcome Module

Data Probe





Start Slicer

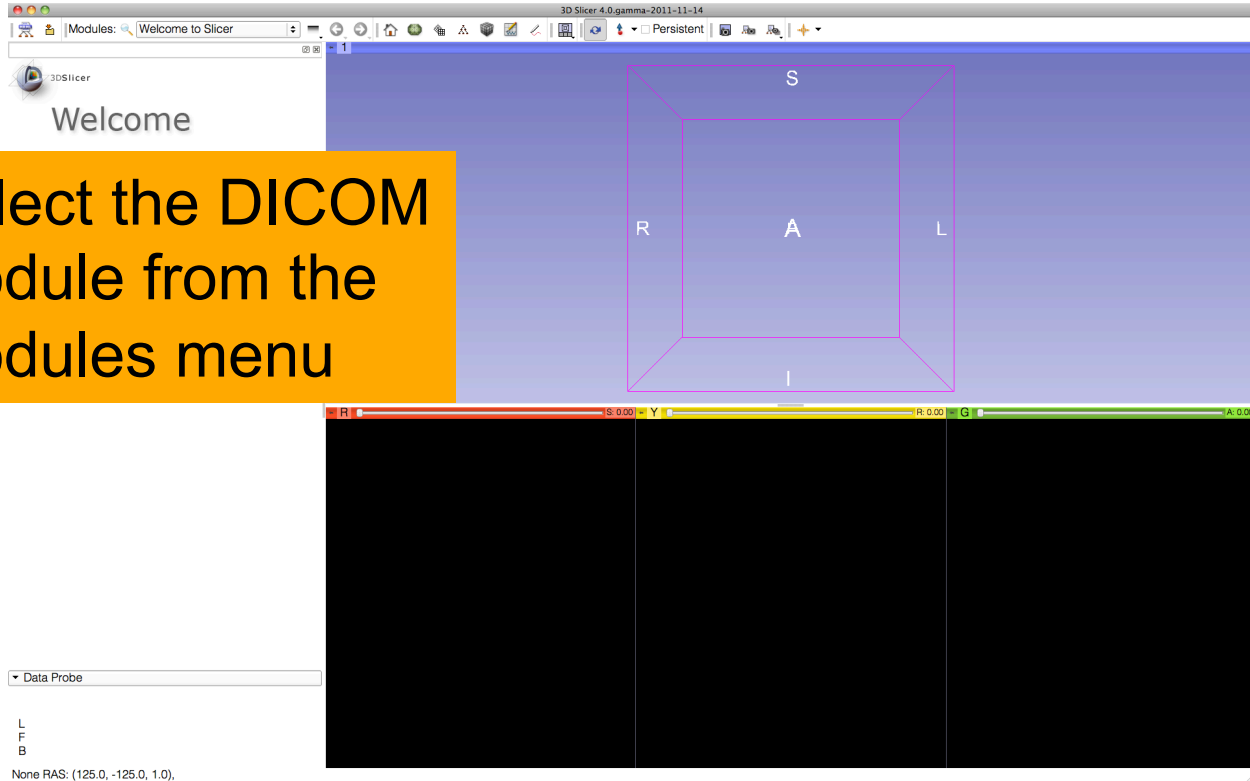


Click on **Welcome to Slicer** to display the 92 modules of Slicer in the Modules menu



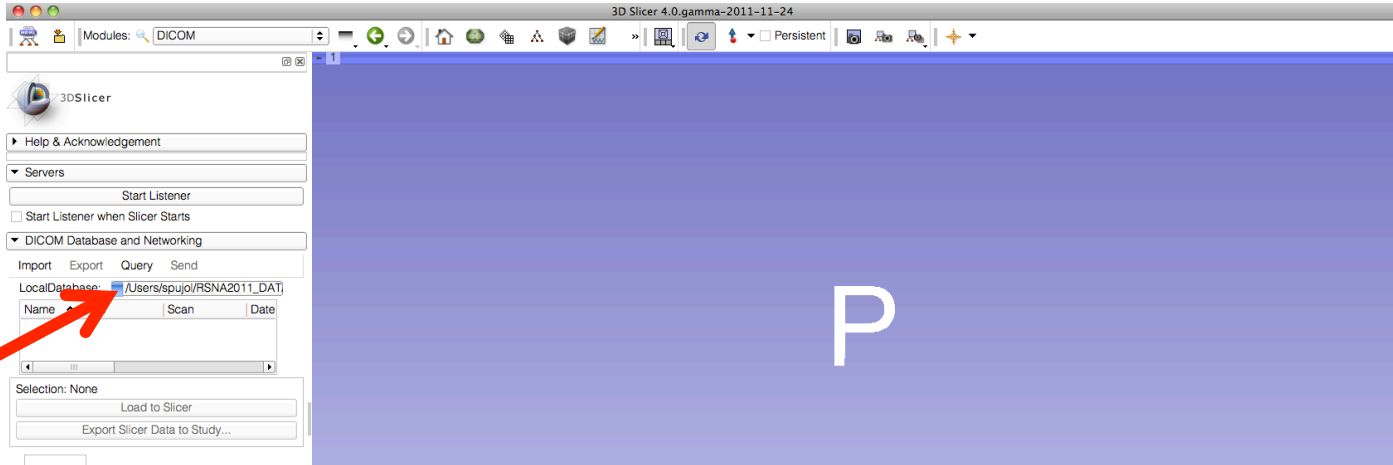
DICOM Module

Select the DICOM module from the Modules menu


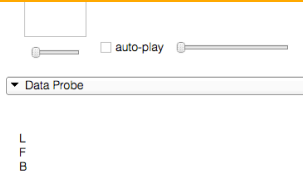




DICOM module

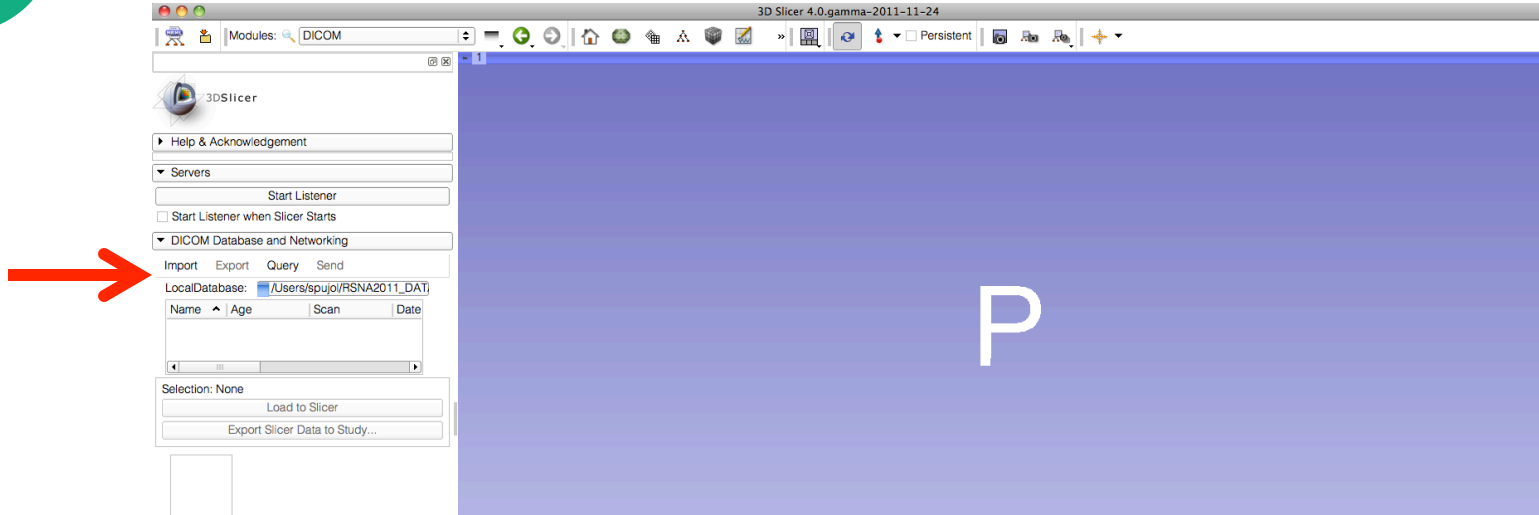


Enter the path to the directory where you would like to install the **Slicer-dicom** database on your machine.





DICOM module

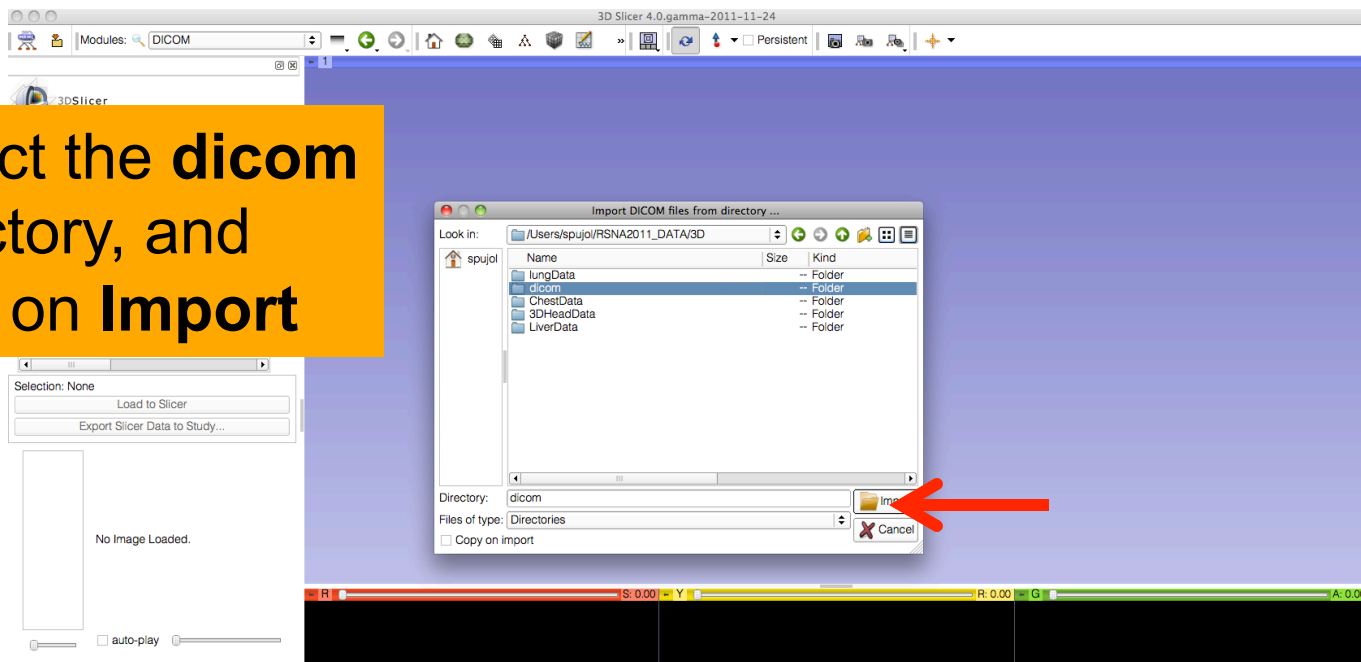


Click on **Import**, and browse to the location of the **dicom** directory, located in **C:\Documents and Settings\Administrator\Desktop\3D**



DICOM module

Select the **dicom** directory, and click on **Import**

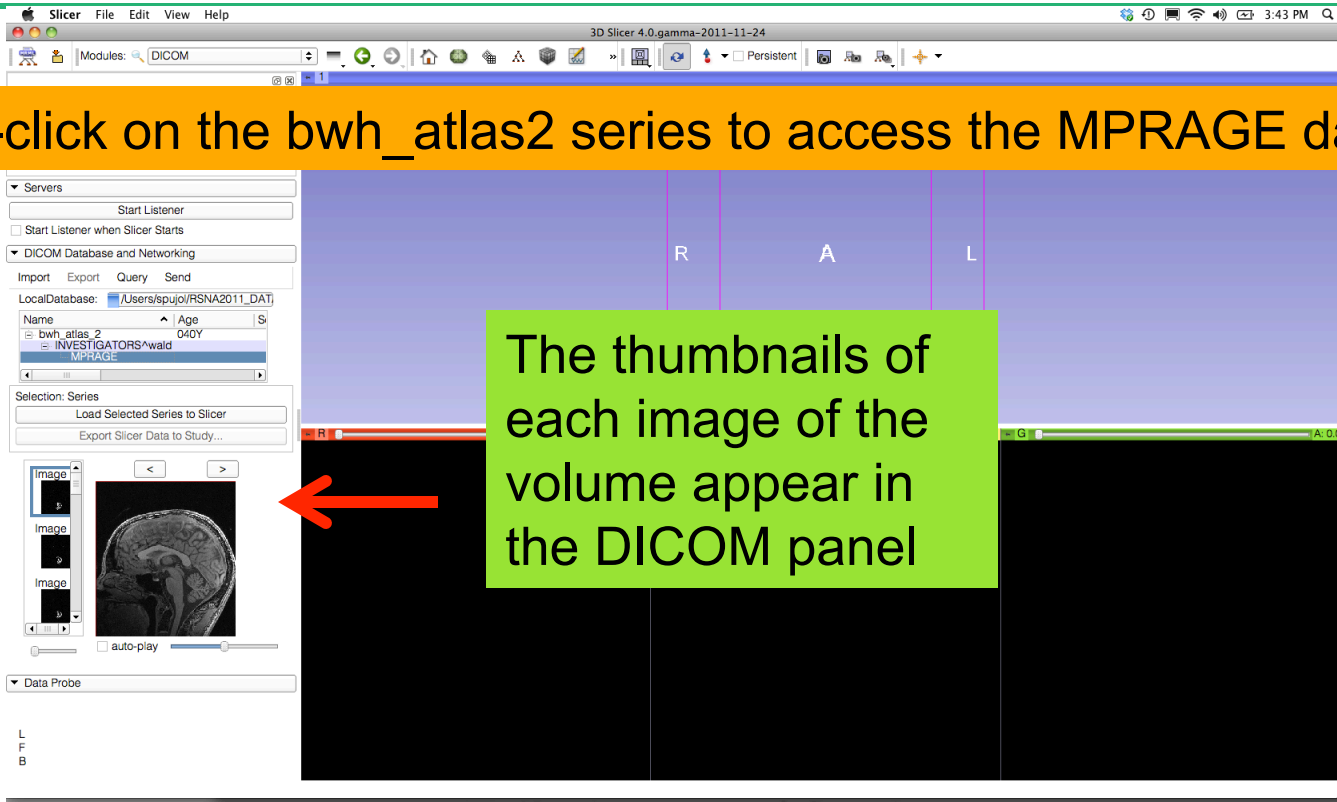


Note: Loading the dicom dataset in the database may take a few minutes.



DICOM module

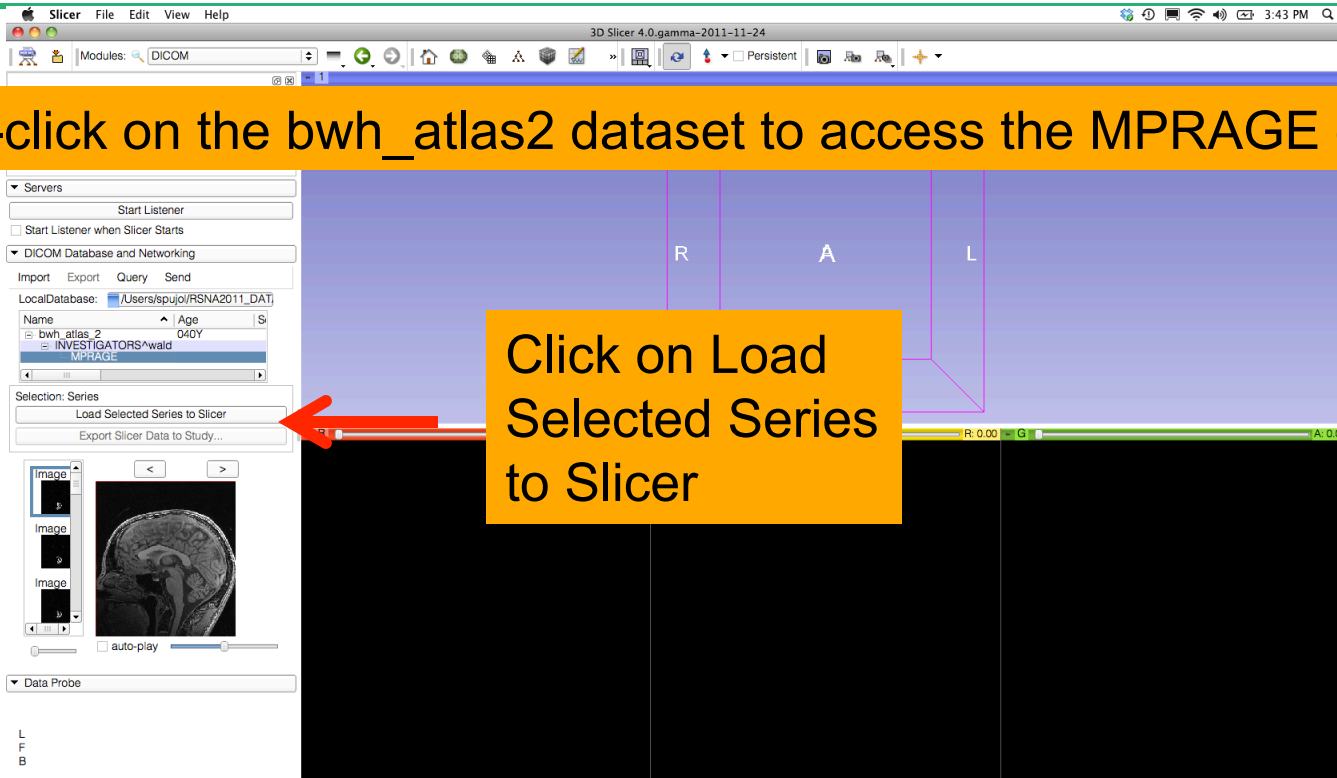
Double-click on the bwh_atlas2 series to access the MPRAGE dataset.





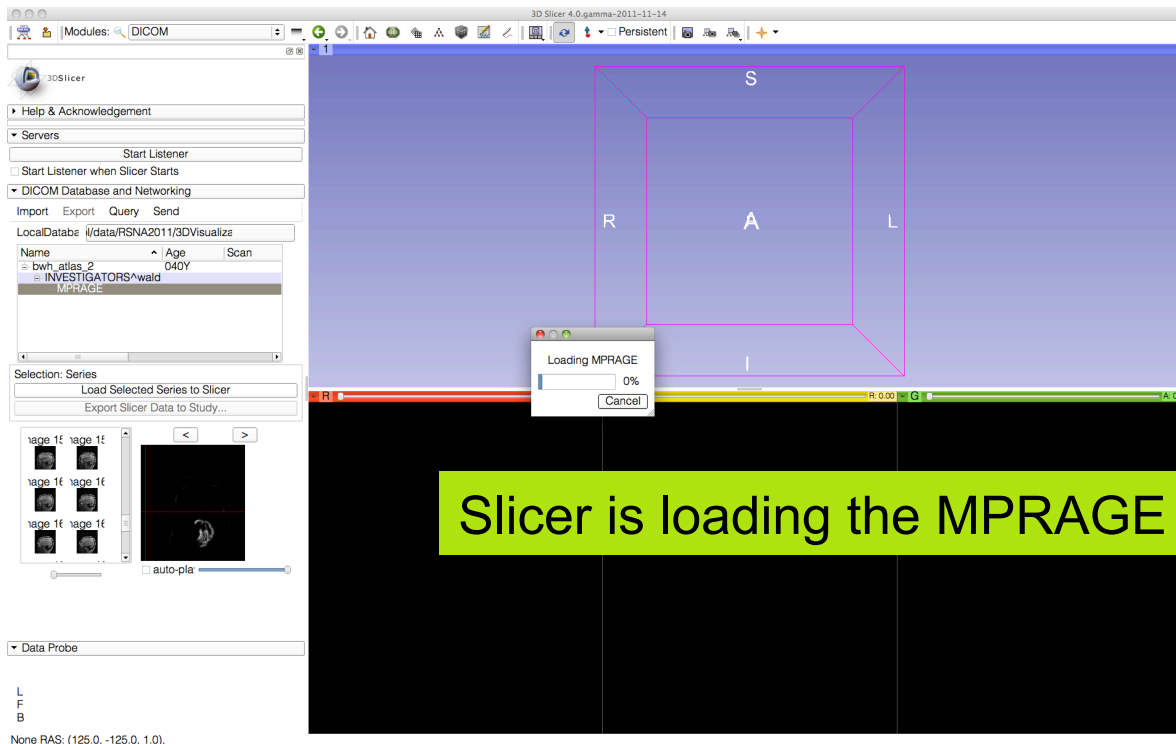
DICOM module

Double-click on the bwh_atlas2 dataset to access the MPRAGE dataset.





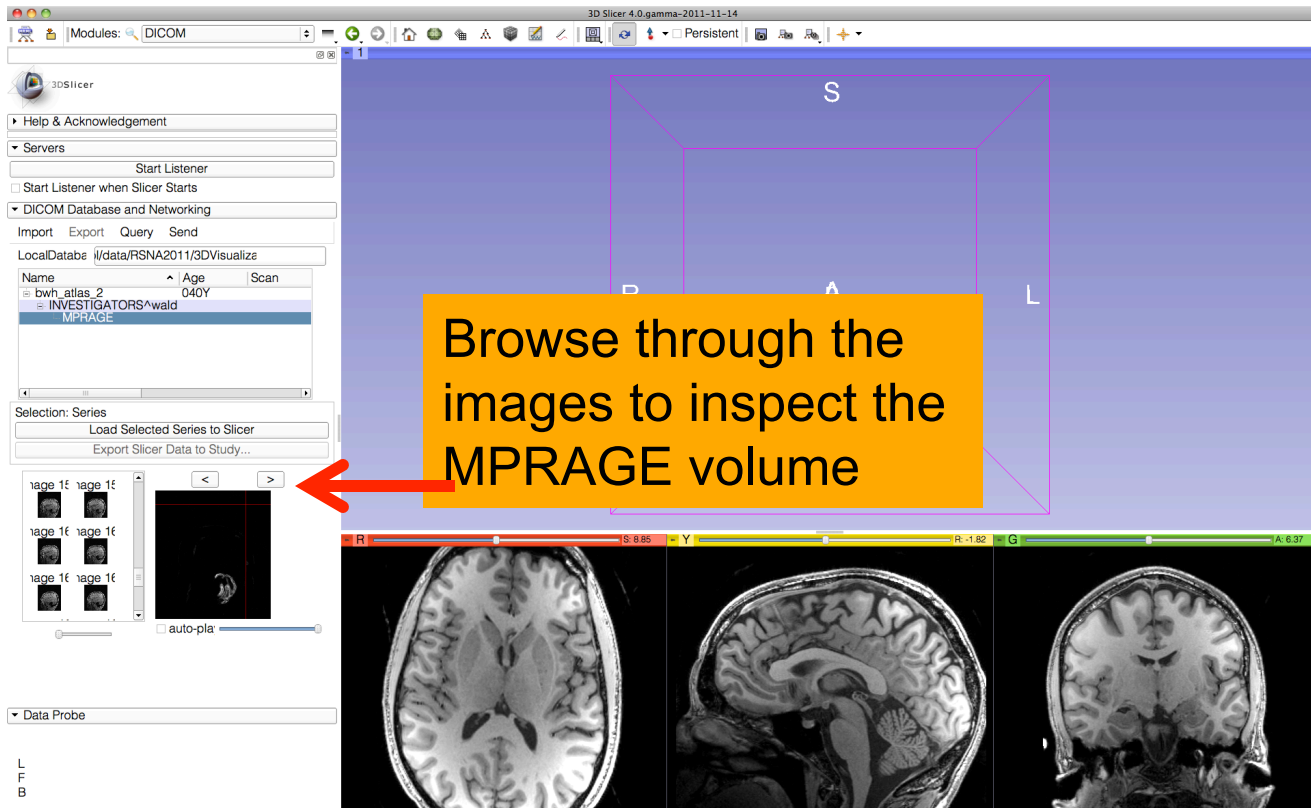
DICOM module



Slicer is loading the MPRAGE dataset



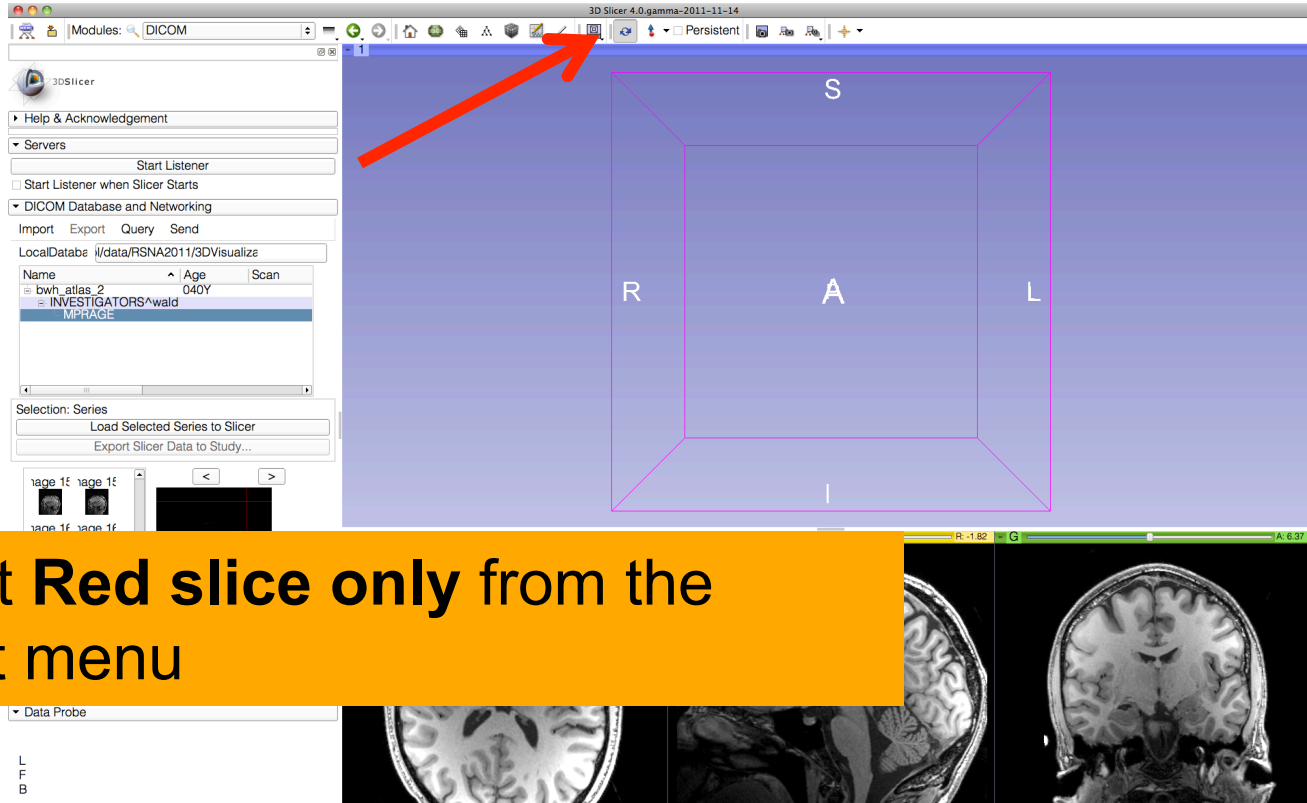
DICOM module



Browse through the images to inspect the MPRAGE volume



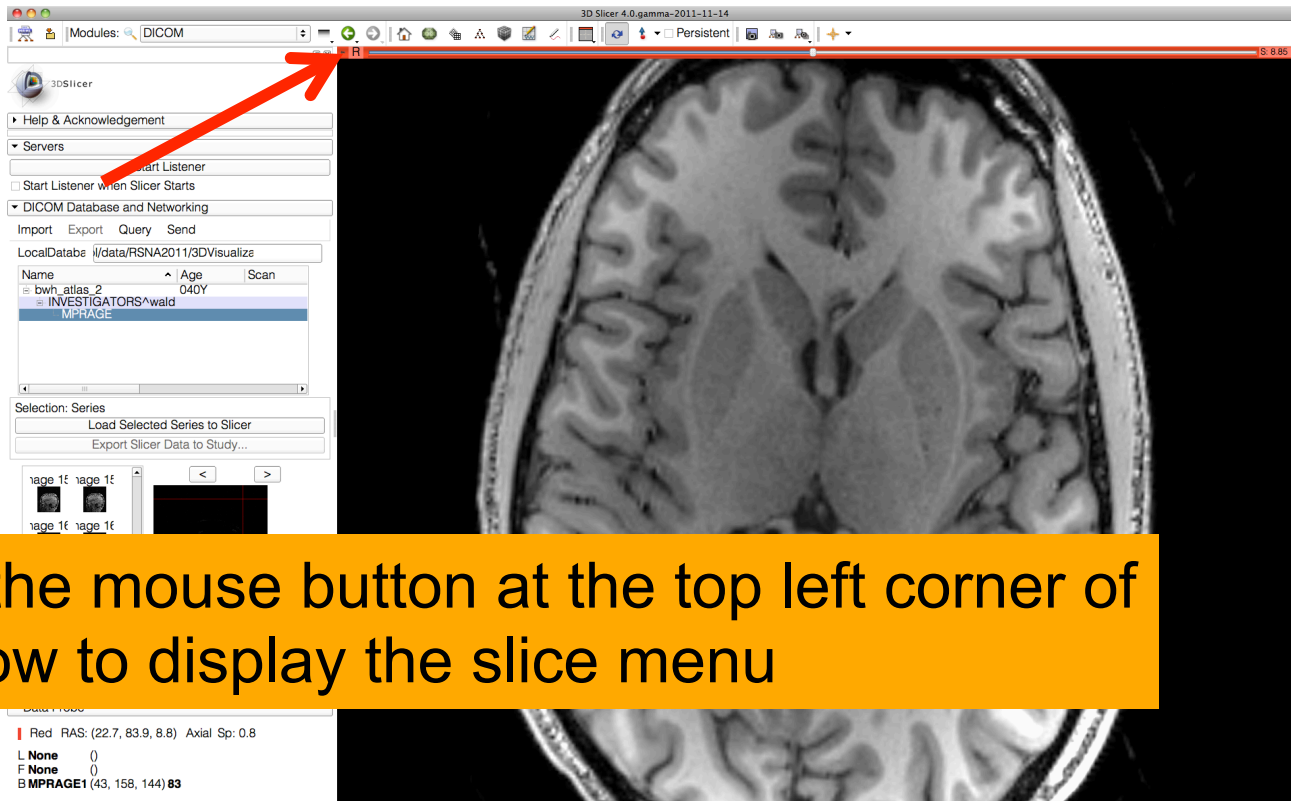
DICOM module



Select Red slice only from the layout menu



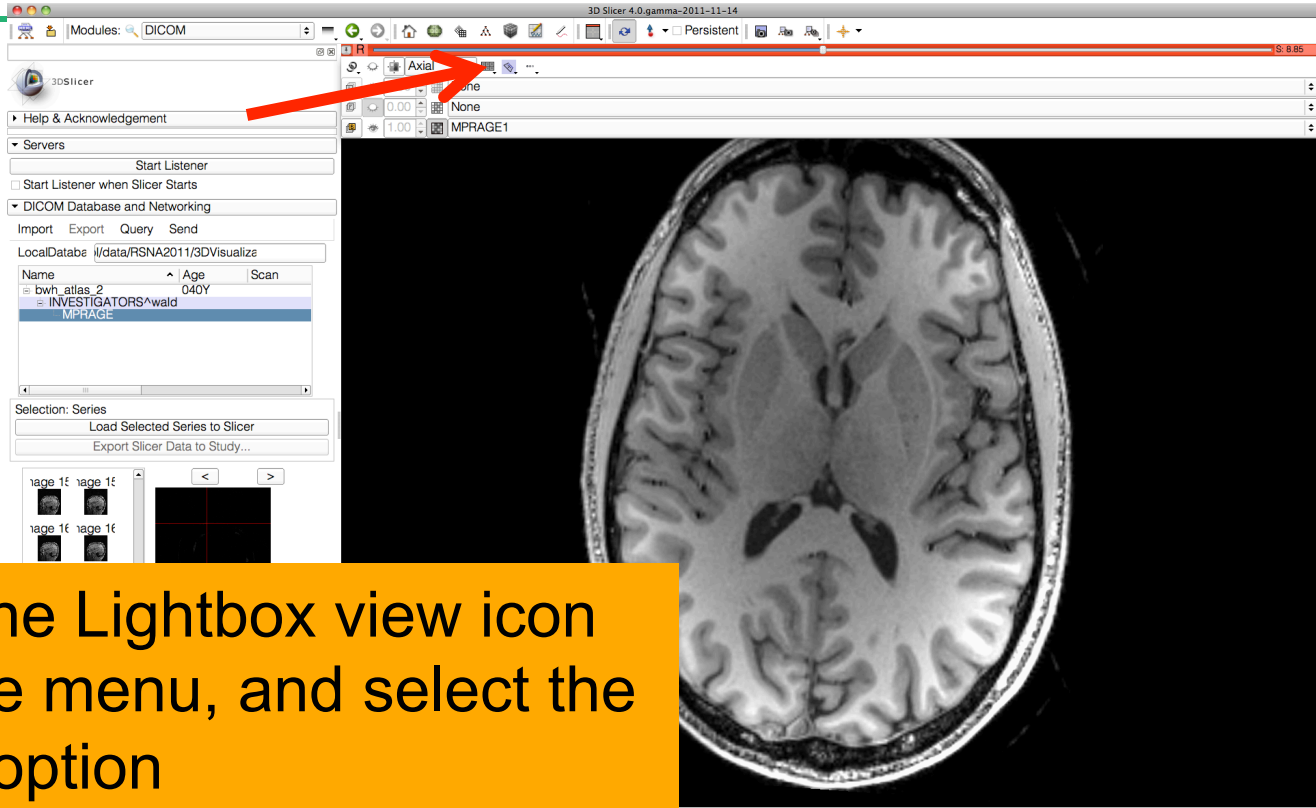
DICOM module



Position the mouse button at the top left corner of the window to display the slice menu



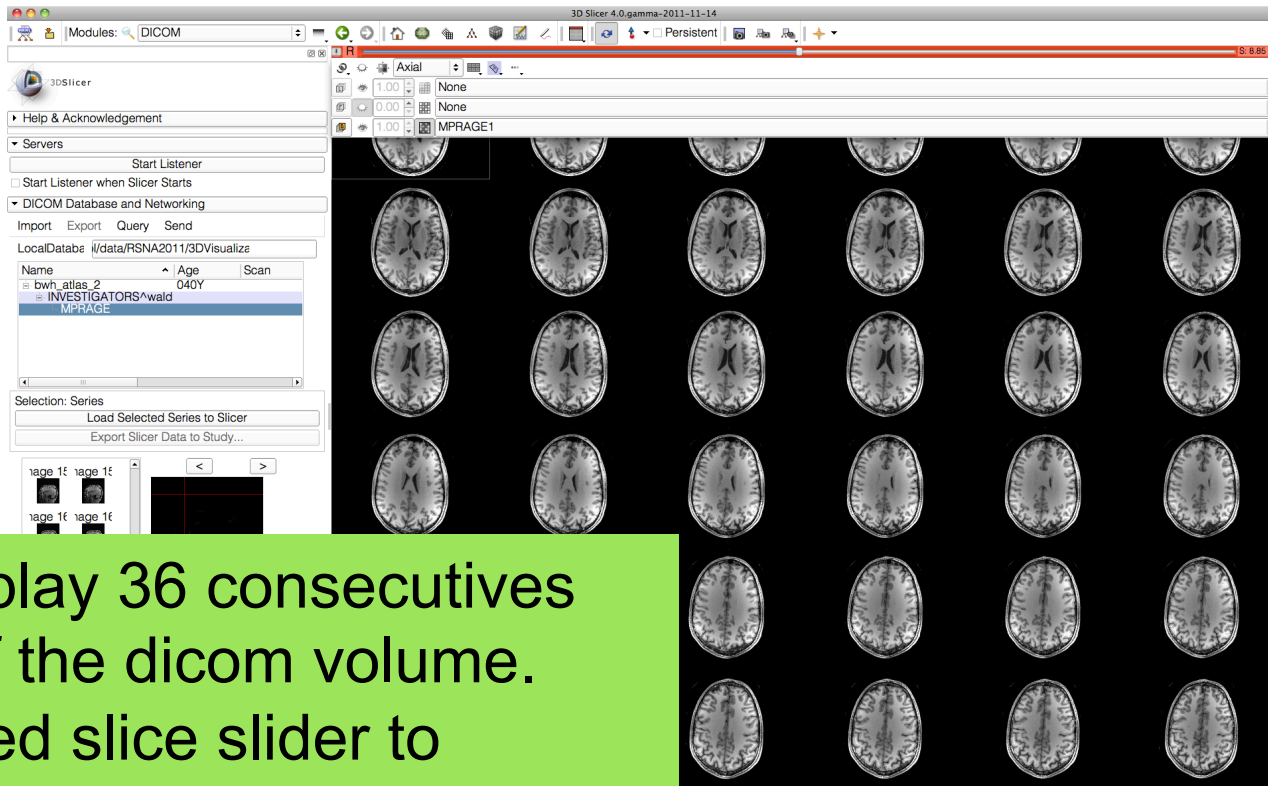
DICOM module



Click on the Lightbox view icon in the slice menu, and select the 6x6 view option



DICOM module

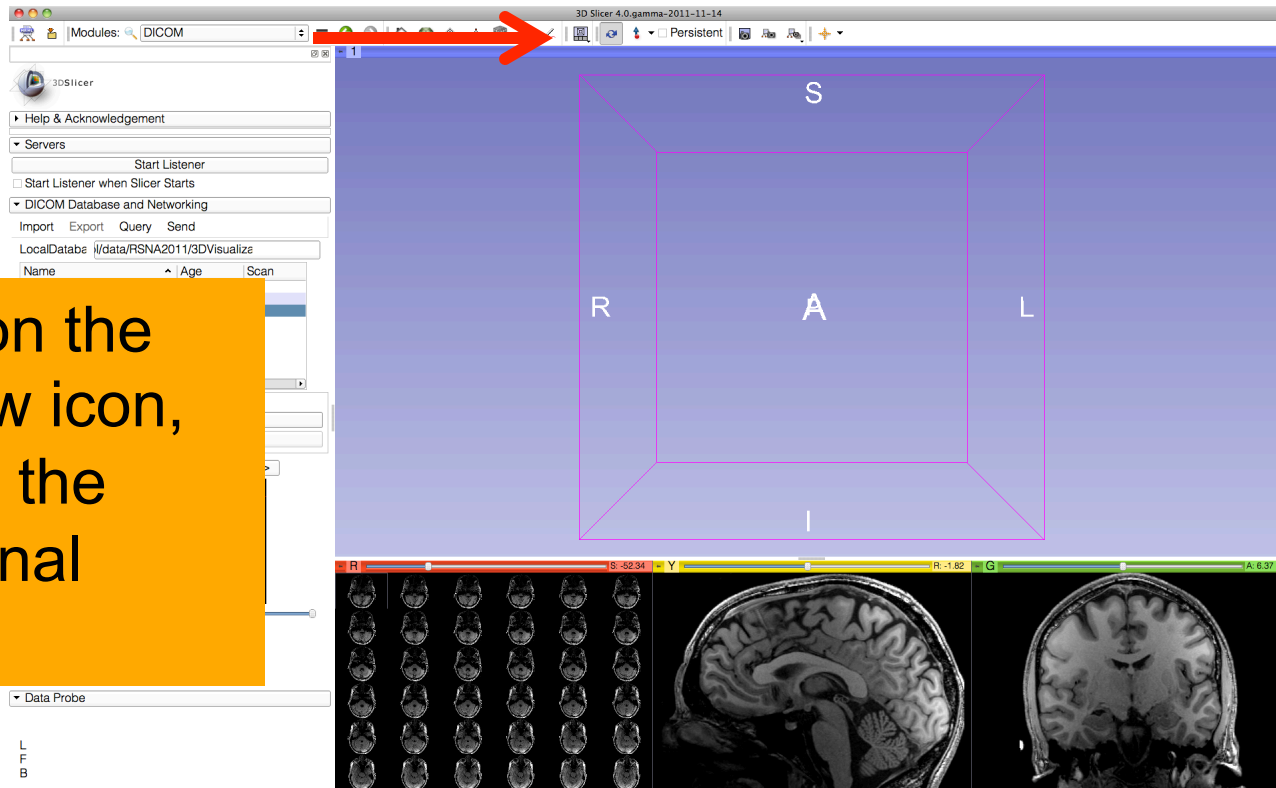


Slicer display 36 consecutives images of the dicom volume.
Use the red slice slider to browse through the dicom data



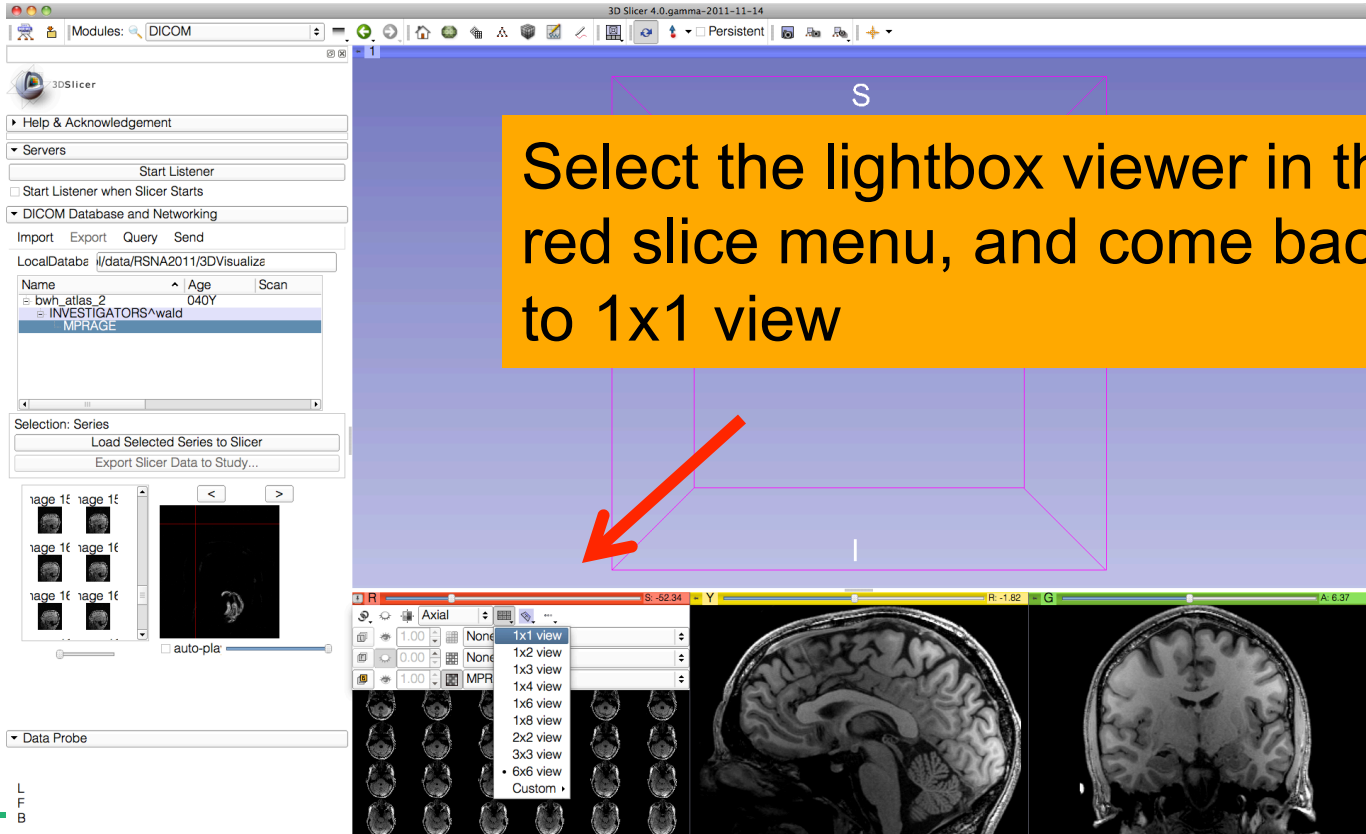
DICOM module

Left click on the red window icon, and select the Conventional layout





DICOM module





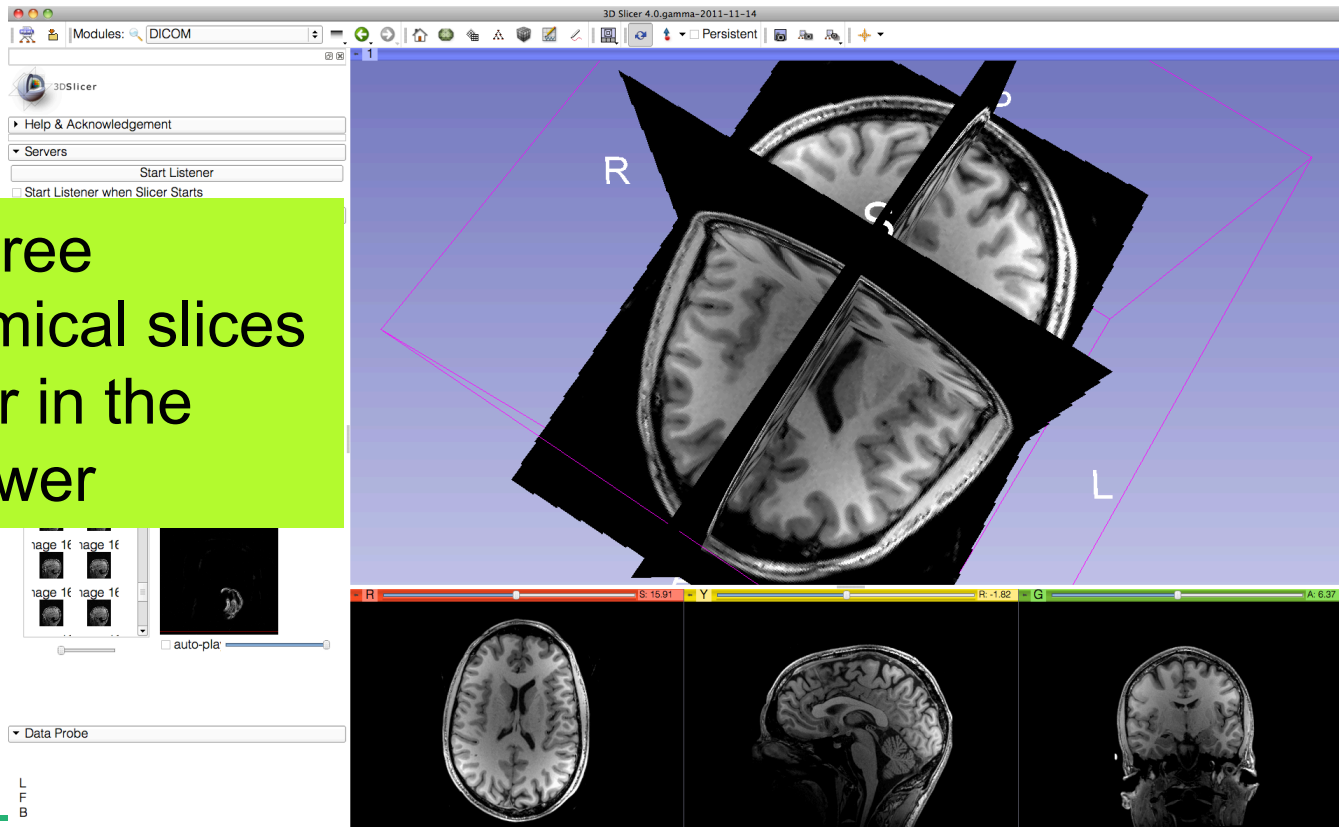
DICOM module

The screenshot shows the 3D Slicer DICOM module interface. A yellow callout box with black text reads: "Click on the links icon to link all three viewers, and on the eye icon to display the slices in the 3D Viewer". A red circle highlights the 'links' icon in the viewer toolbar, and a red arrow points to the 'eye' icon. The interface includes a 'LocalDatabase' table with columns 'Name', 'Age', and 'Scan', containing entries like 'bwh_atlas_2' and 'INVESTIGATORS^wald'. The 'Selection: Series' section has buttons for 'Load Selected Series to Slicer' and 'Export Slicer Data to Study...'. The 'Data Probe' section is visible at the bottom left. The main view shows three orthogonal slices (Axial, Sagittal, Coronal) of a brain MRI scan.



DICOM module

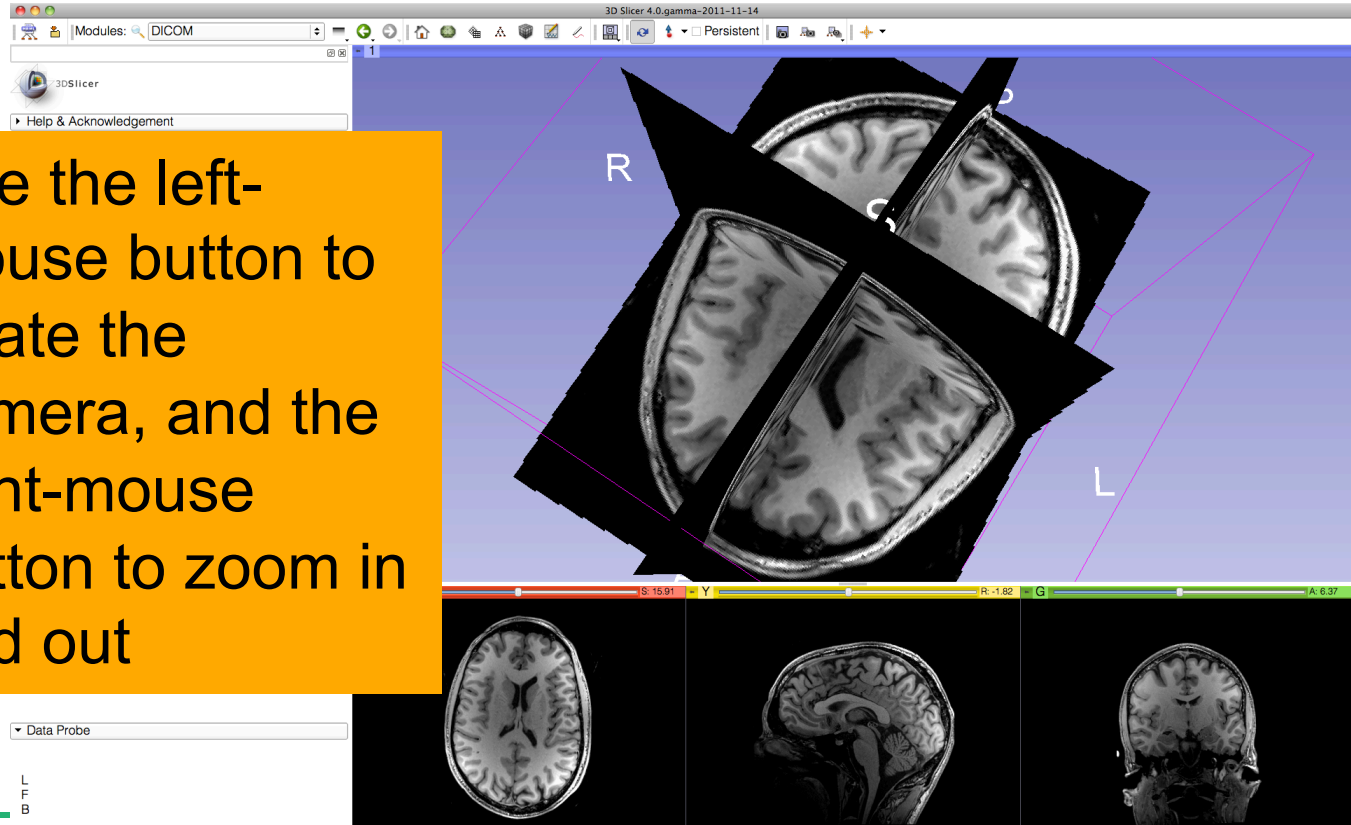
The three anatomical slices appear in the 3DViewer





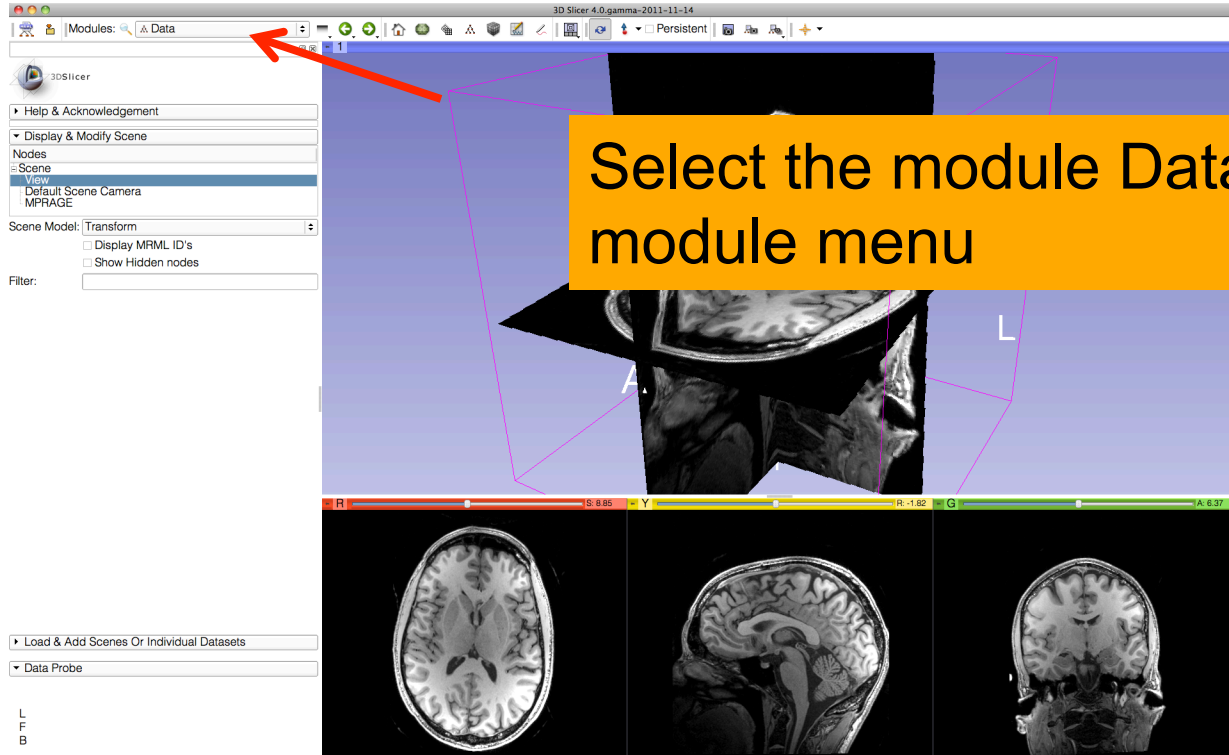
DICOM module

Use the left-
mouse button to
rotate the
camera, and the
right-mouse
button to zoom in
and out





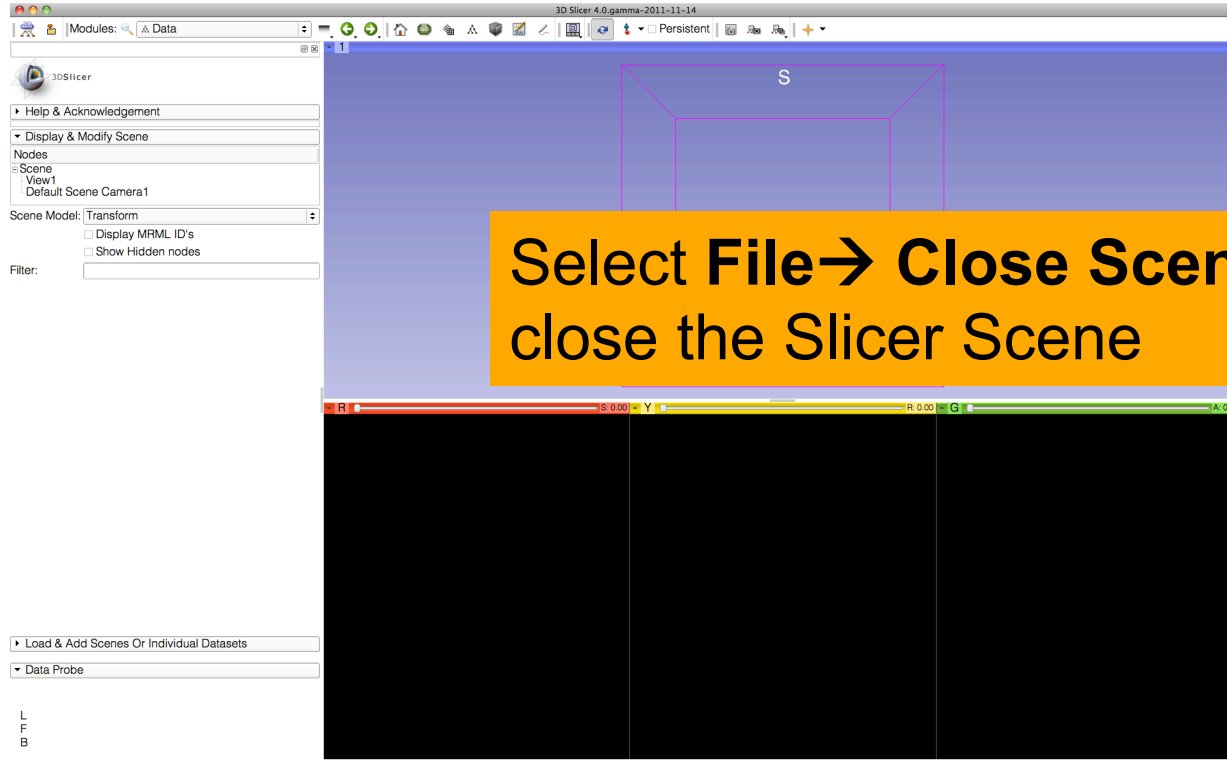
DICOM module

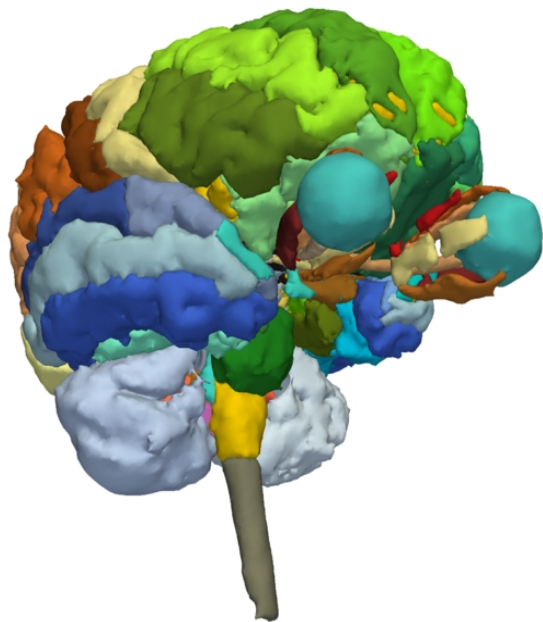


Select the module Data from the module menu



Close the Scene



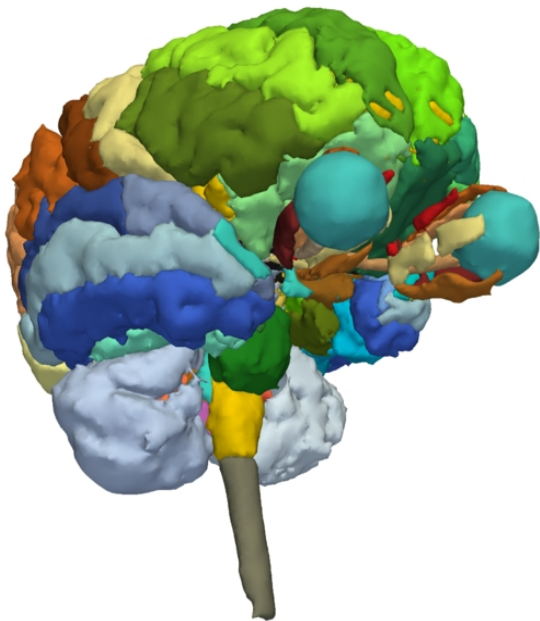


Part 2:

3D visualization of surface models of the brain



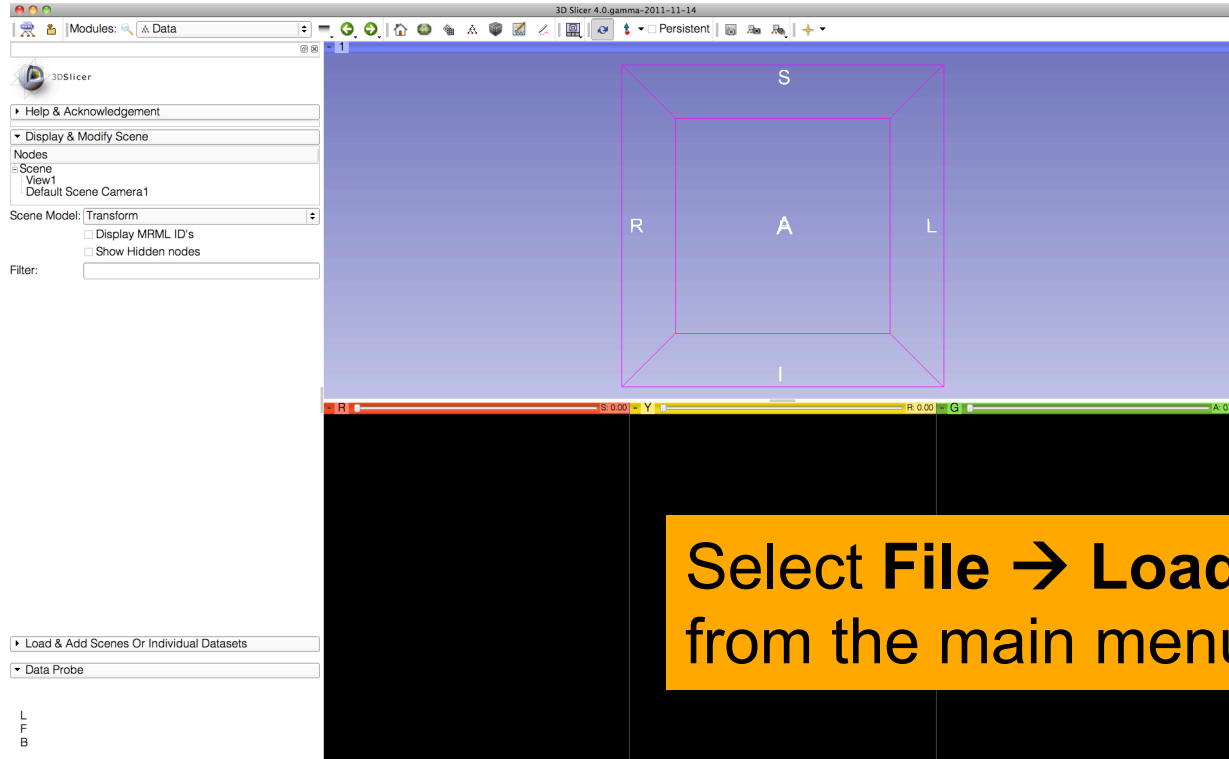
3D Slicer Scene



- A Slicer scene is a MRML file which contains a list of elements loaded into Slicer (volumes, models, fiducials...)
- The tutorial scene contains an MR scan of the brain and 3D surface models of anatomical structures.

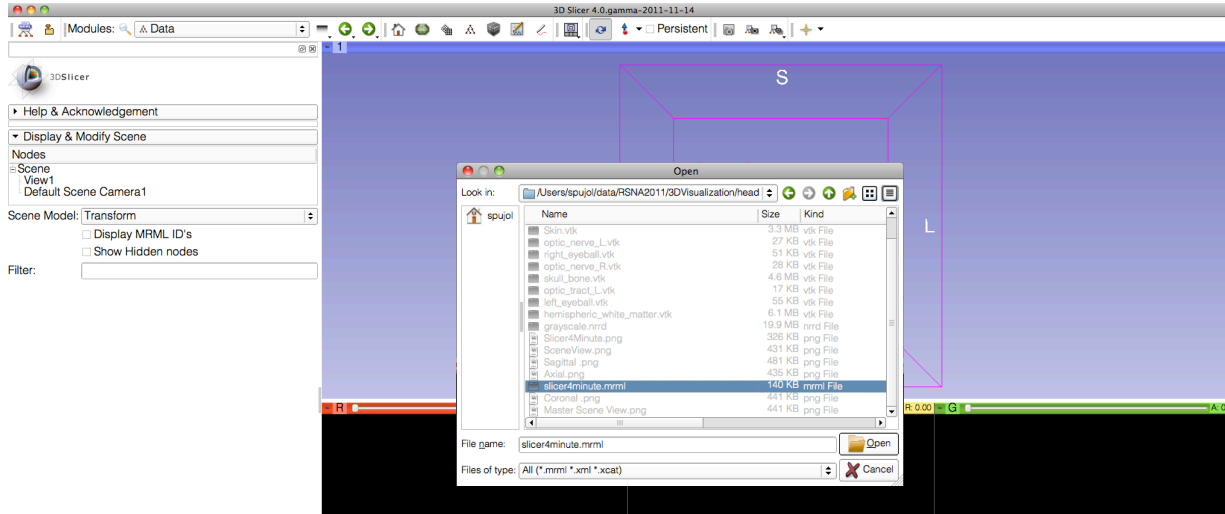


Loading a Scene





Loading a Scene

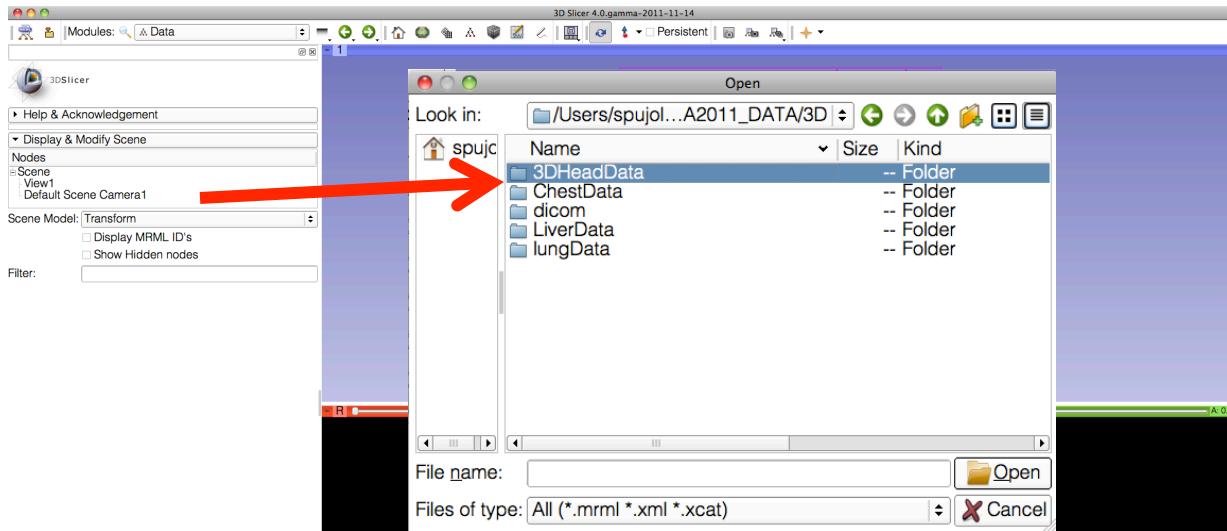


Browse to the directory **3D**, located on the Desktop:

C:\Documents and Settings\Administrator\Desktop\3D



Loading a Scene

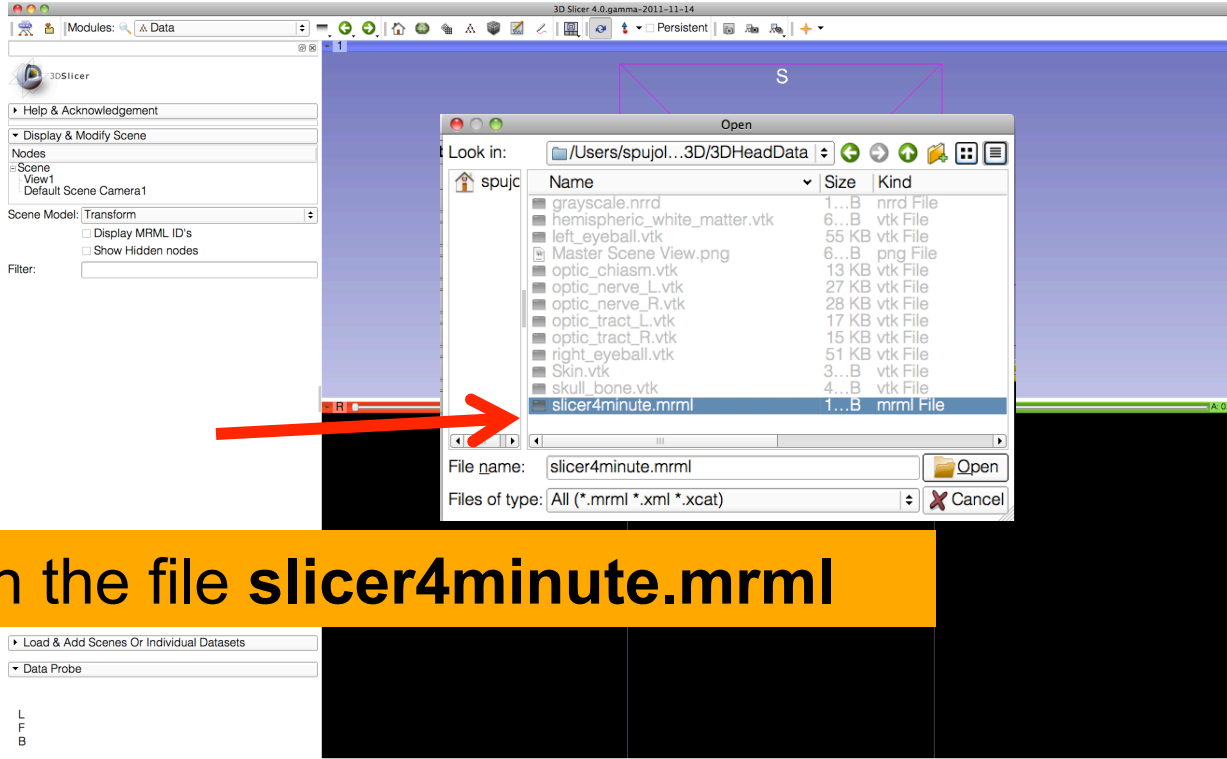


Select the directory **3DHeadData**, and open the file **slicer4minute.mrm**

L
F
B



Loading a Scene

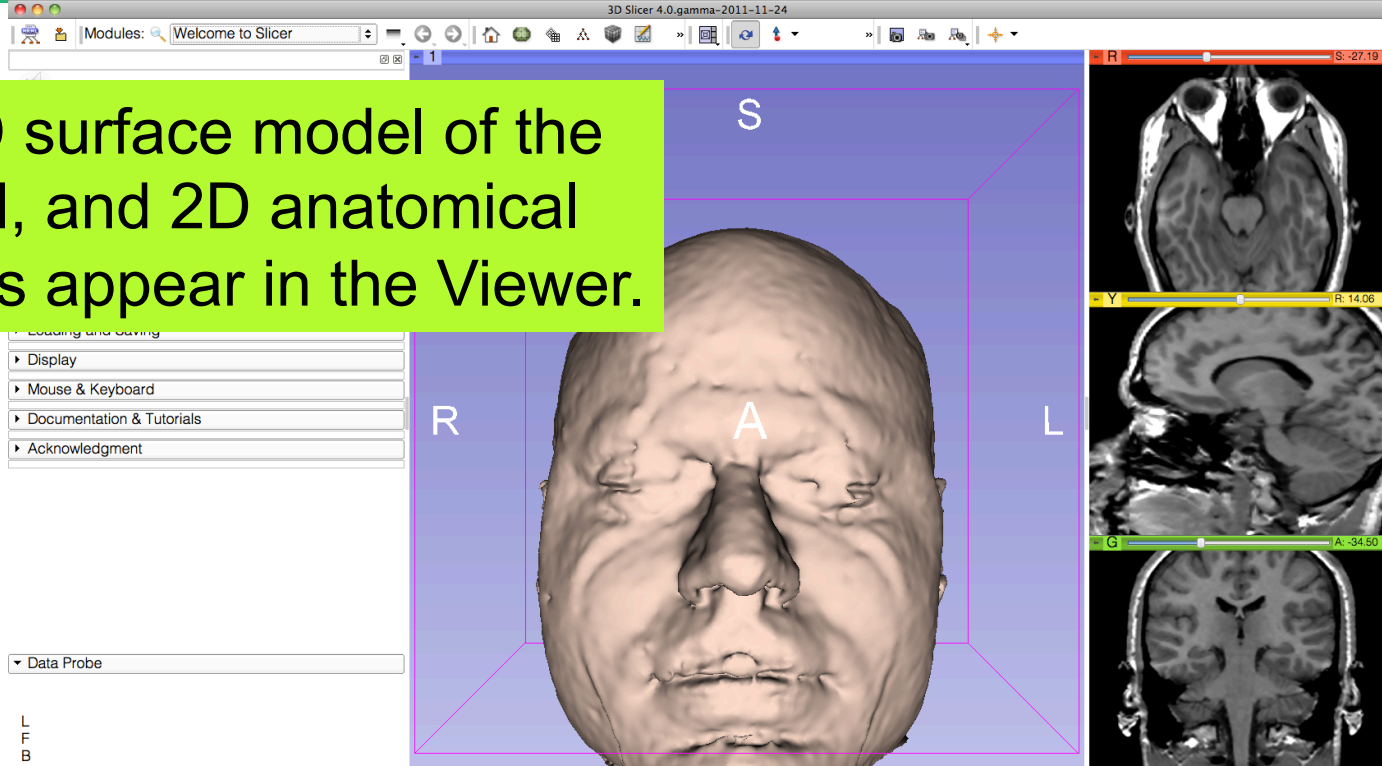


Open the file **slicer4minute.mrml**



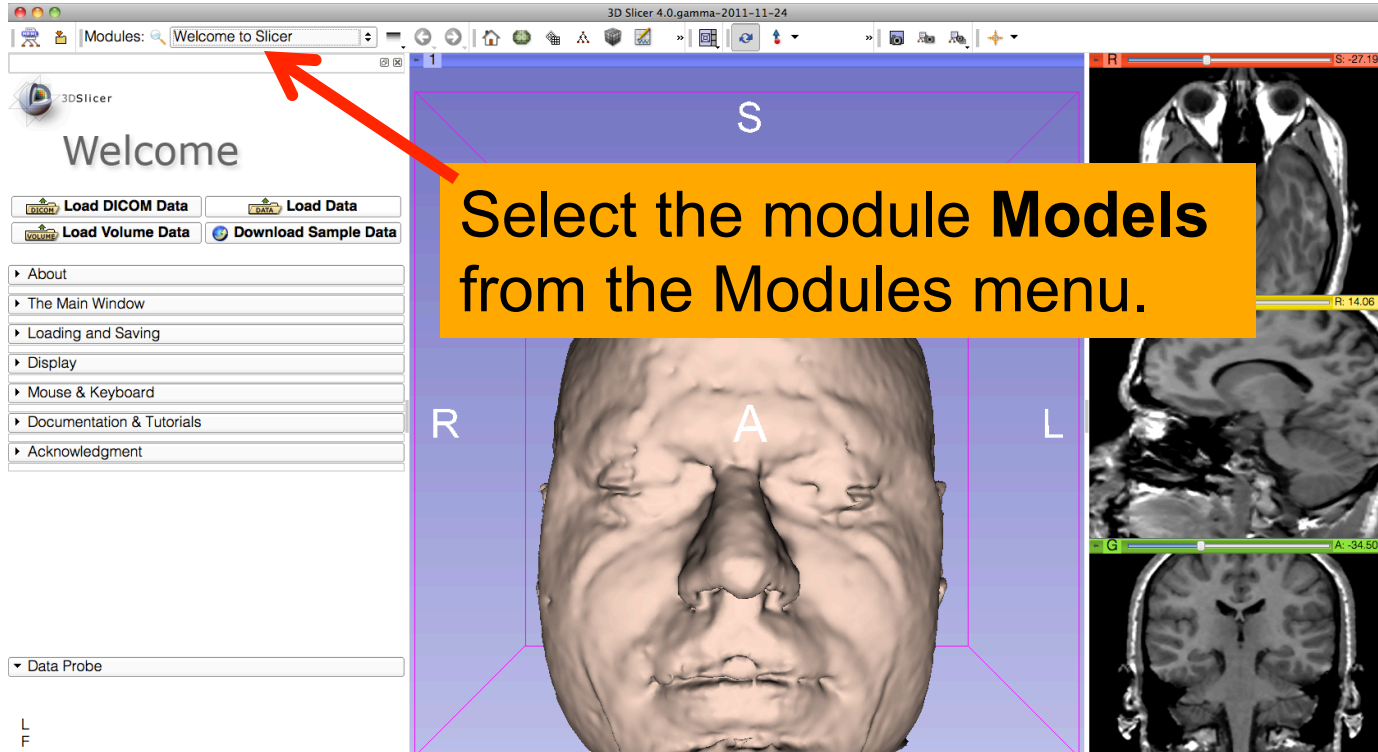
Loading the Slicer Scene

A 3D surface model of the head, and 2D anatomical slices appear in the Viewer.



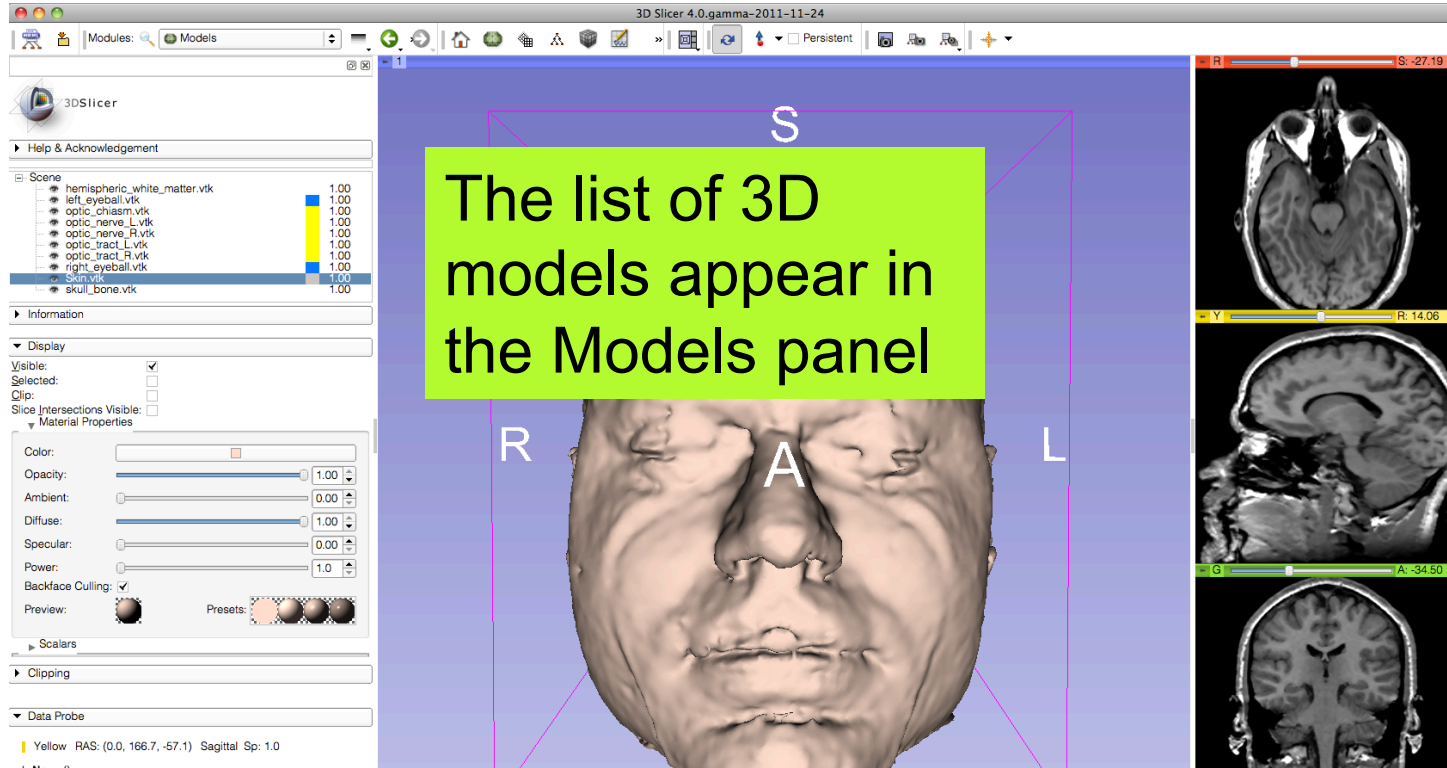


Loading the Slicer Scene



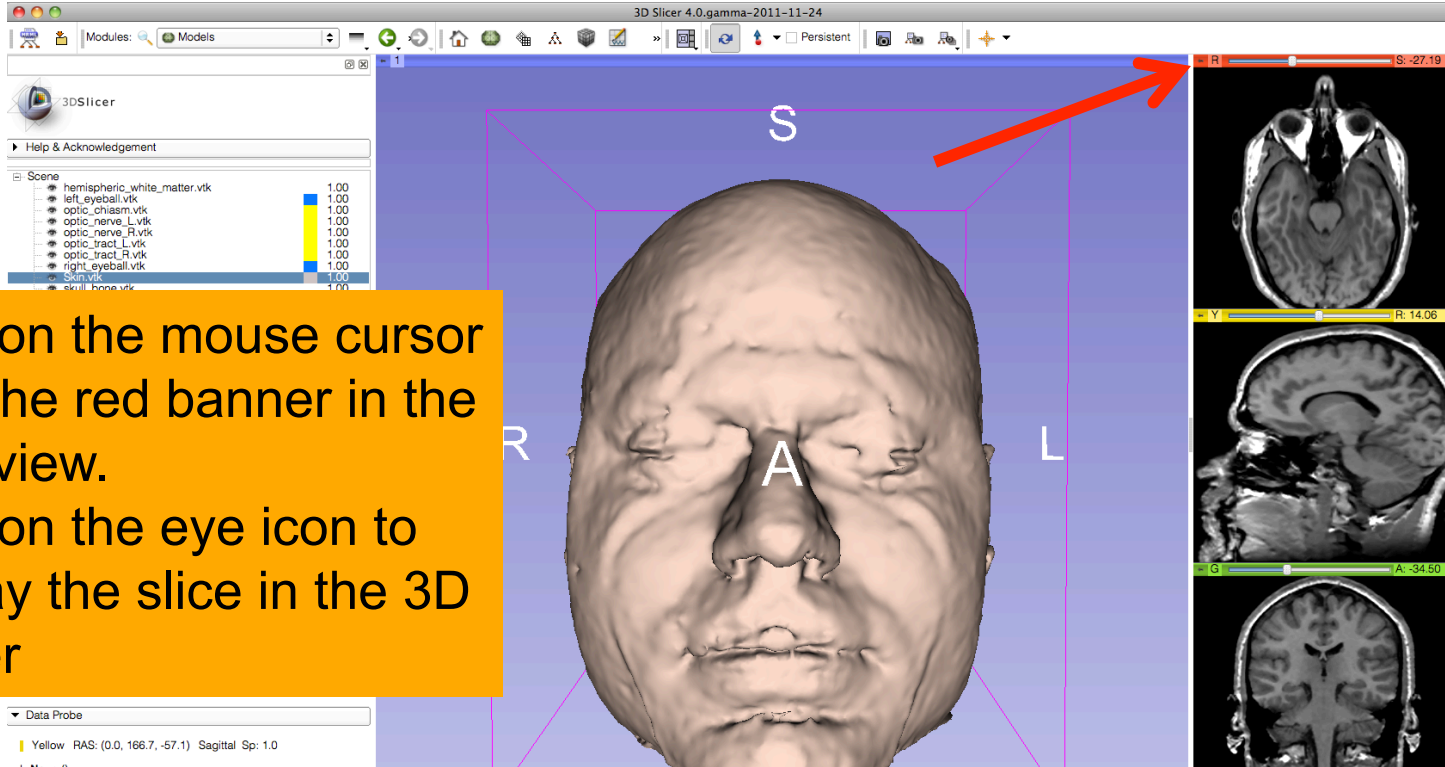


Models module





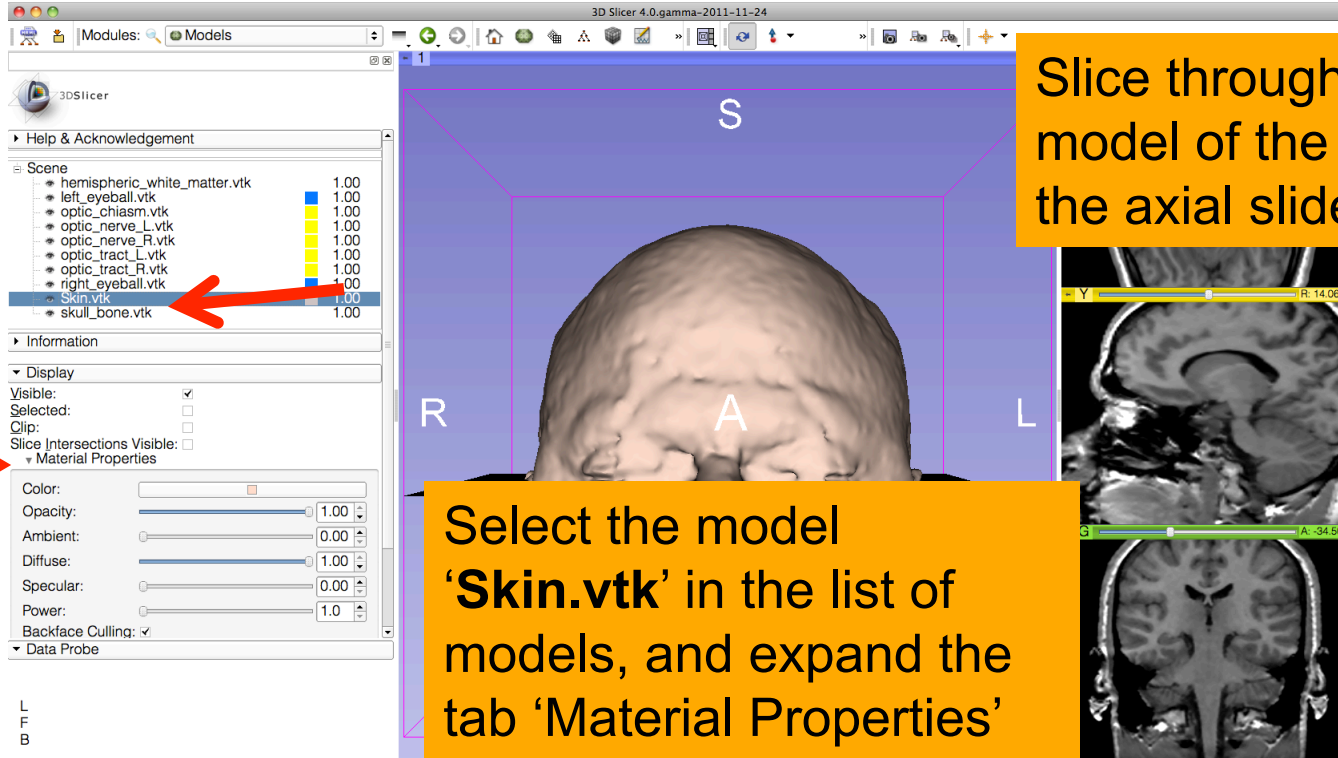
3D Visualization



Position the mouse cursor over the red banner in the axial view. Click on the eye icon to display the slice in the 3D viewer



3D Visualization

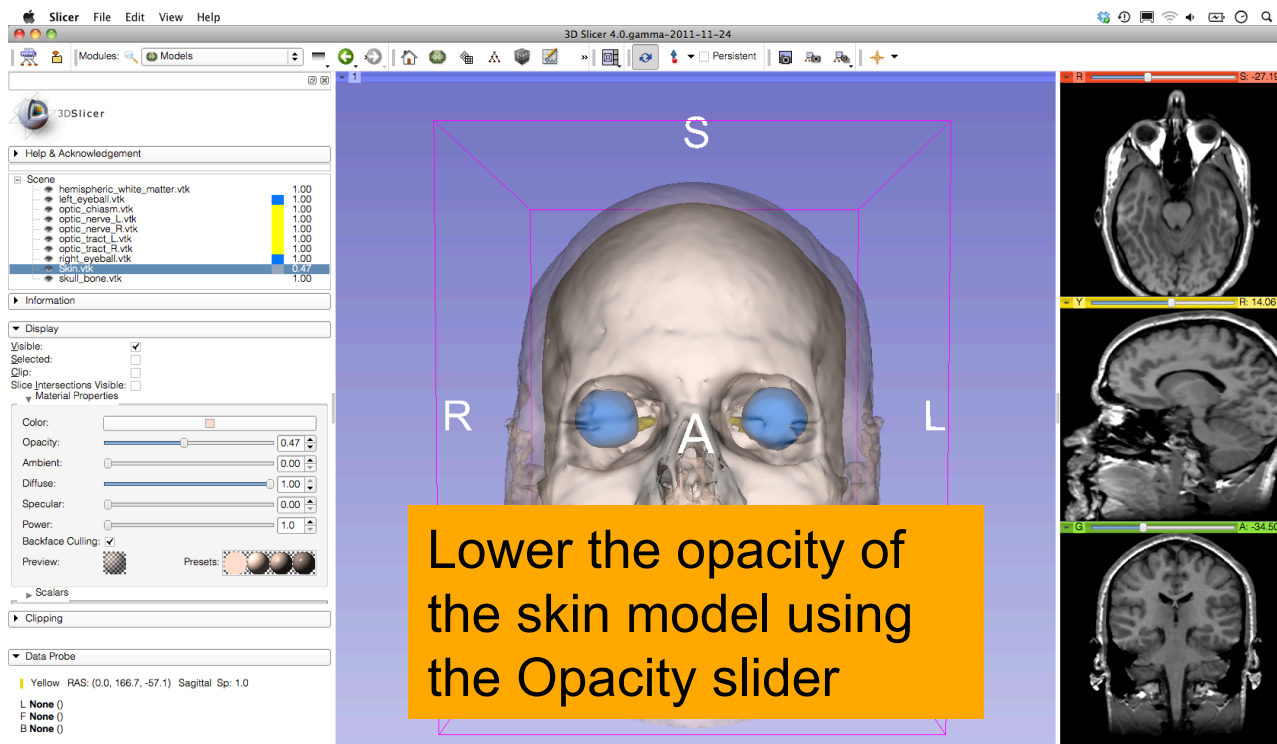


Slice through the 3D model of the head using the axial slider

Select the model 'Skin.vtk' in the list of models, and expand the tab 'Material Properties' under 'Display'

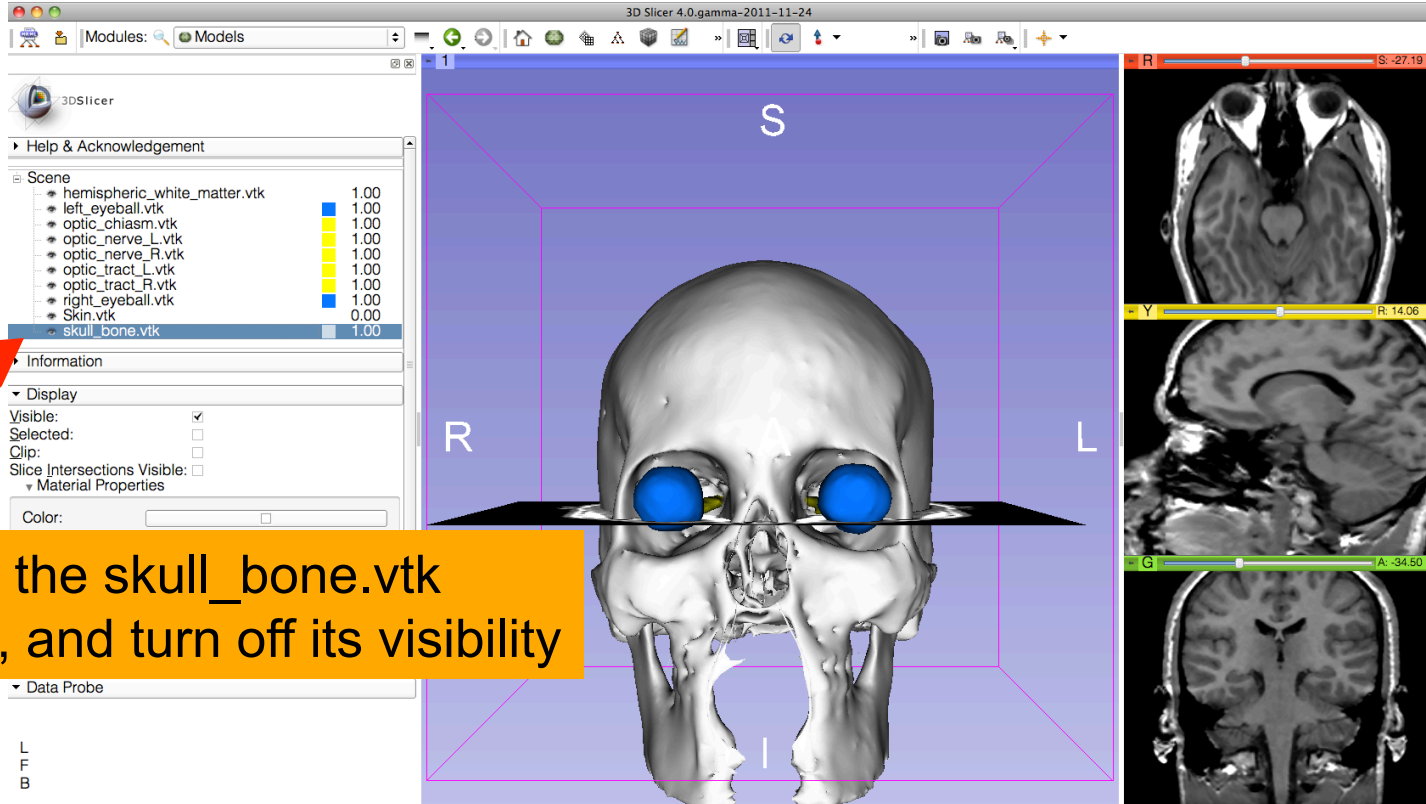


3D Visualization





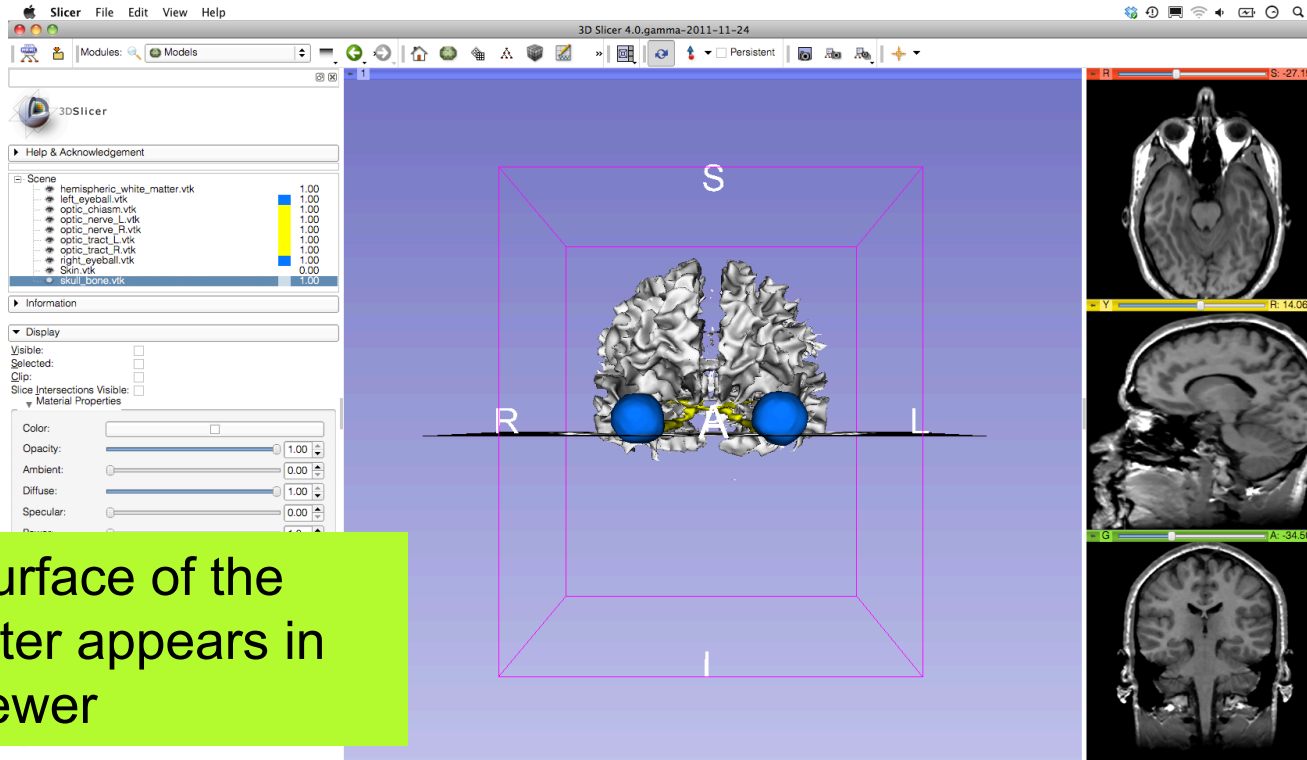
3D Visualization



Select the skull_bone.vtk model, and turn off its visibility



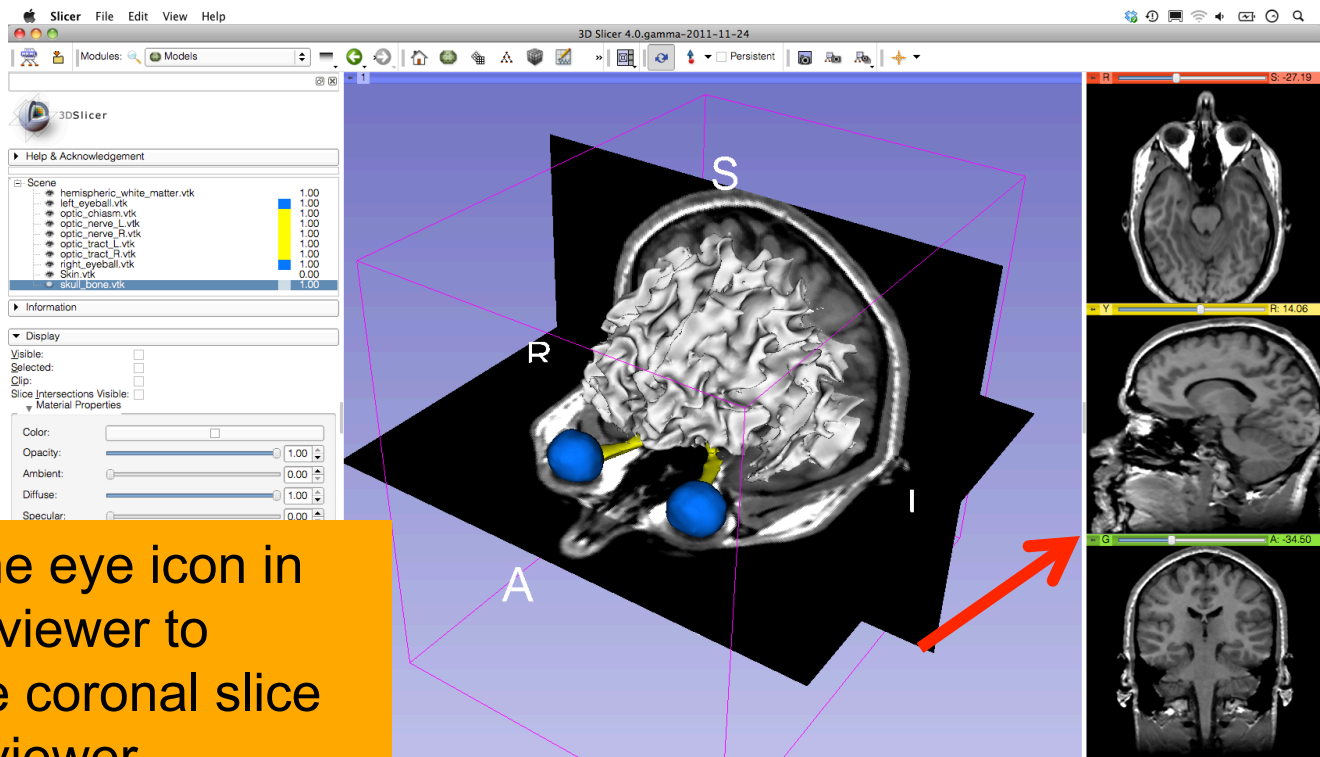
3D Visualization



The 3D surface of the white matter appears in the 3D viewer



3D Visualization



Click on the eye icon in the green viewer to display the coronal slice in the 3D viewer



3D Visualization

3D Slicer 4.0.gamma-2011-11-24

Modules: Models

3DSlicer

Help & Acknowledgement

Scene

- hemispheric_white_matter.vtk 1.00
- left_eyeball.vtk 1.00
- optic_chiasm.vtk 1.00
- optic_nerve_L.vtk 1.00
- optic_nerve_R.vtk 1.00
- optic_tract_L.vtk 1.00
- optic_tract_R.vtk 1.00
- right_eyeball.vtk 1.00
- Skin.vtk 0.00
- skull_bone.vtk 1.00

Information

Display

Visible:

Selected:

Clip:

Slice Intersections Visible:

Material Properties

Color:

Opacity: 1.00

Ambient: 0.00

Diffuse: 1.00

Specular: 0.00

Power: 1.0

Backface Culling:

Data Probe

L
F
B

S

R -27.19

R 14.06

A -34.50

Select the 3D model **hemispheric_white_matter.vtk**, and select the option **Clip** in the Display tab



3D Visualization

The screenshot shows the 3D Slicer 4.0 interface. The main window displays a 3D brain model with three intersecting clipping planes: a blue plane labeled 'S' (Superior-Inferior), a yellow plane labeled 'A' (Anterior-Posterior), and a green plane labeled 'L' (Lateral-Medial). A blue sphere is visible on the brain model. The left sidebar contains the 'Models' panel with '3DSlicer' selected, and the 'Clipping' panel. The 'Clipping' panel shows the following settings:

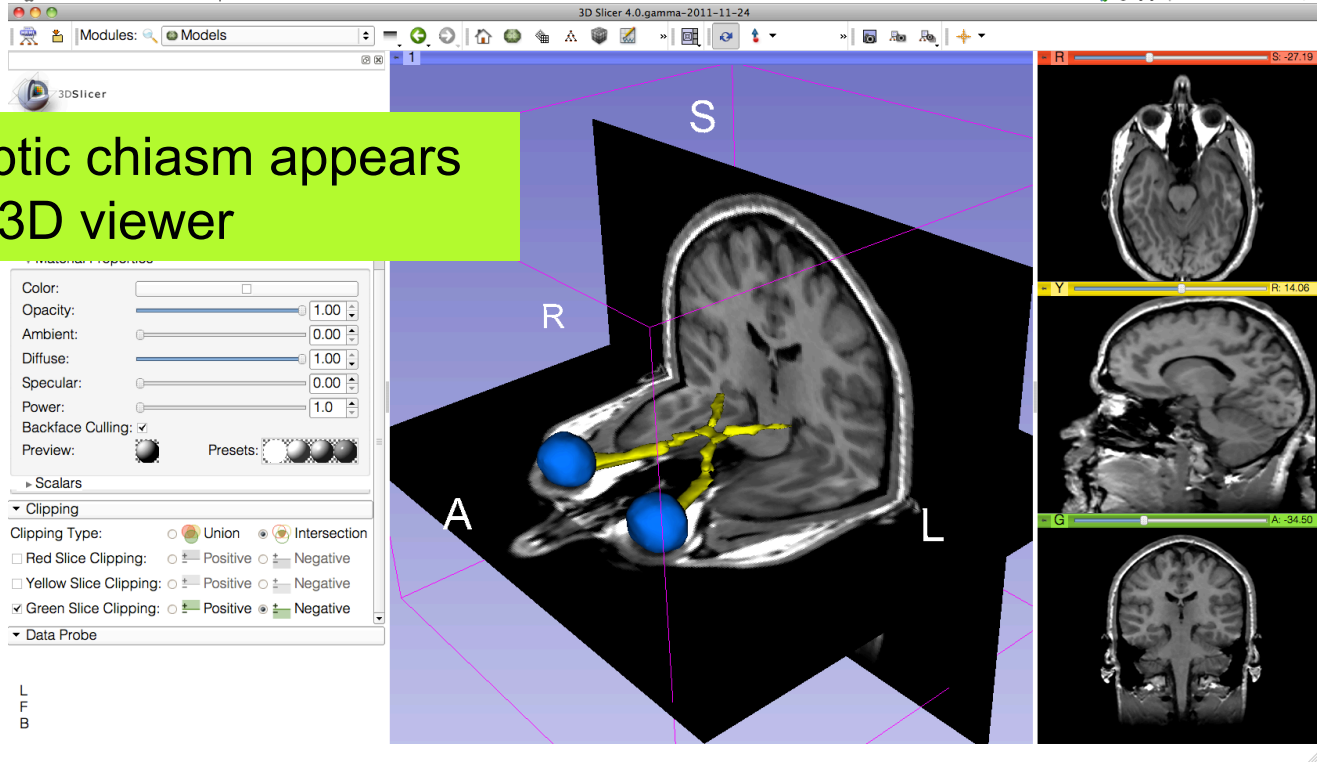
- Clipping Type: Union Intersect
- Red Slice Clipping: Positive Negative
- Yellow Slice Clipping: Positive Negative
- Green Slice Clipping: Positive Negative

A red arrow points from the 'Green Slice Clipping' section to the 'Negative' radio button. A yellow text box with black text is overlaid on the 3D view, stating: "Select the tab Clipping, and set the Green Slice Clipping to Negative Space".



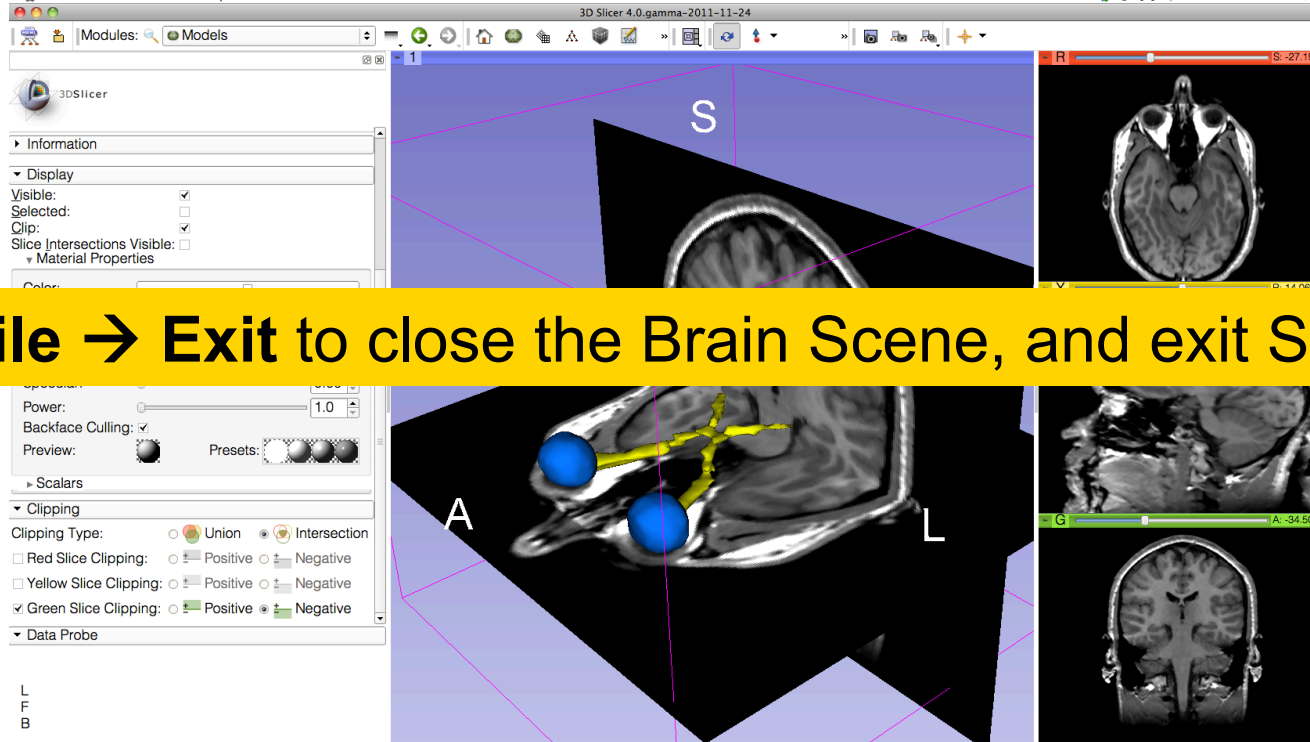
3D Visualization

The optic chiasm appears in the 3D viewer

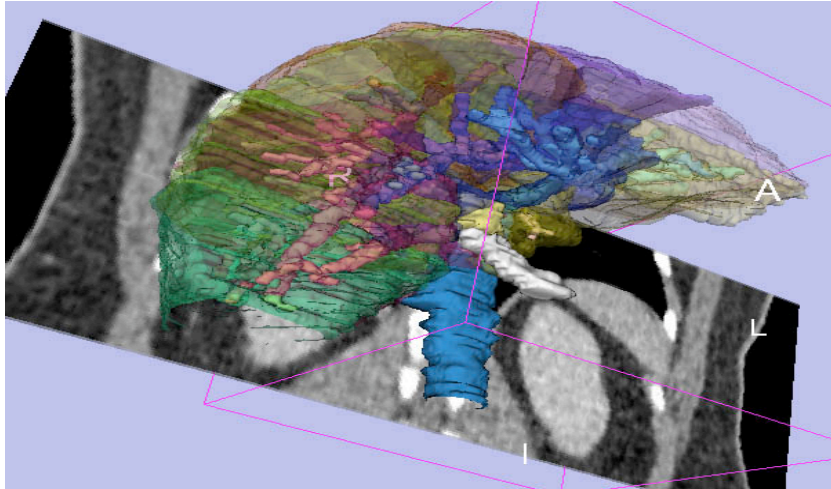




3D Visualization



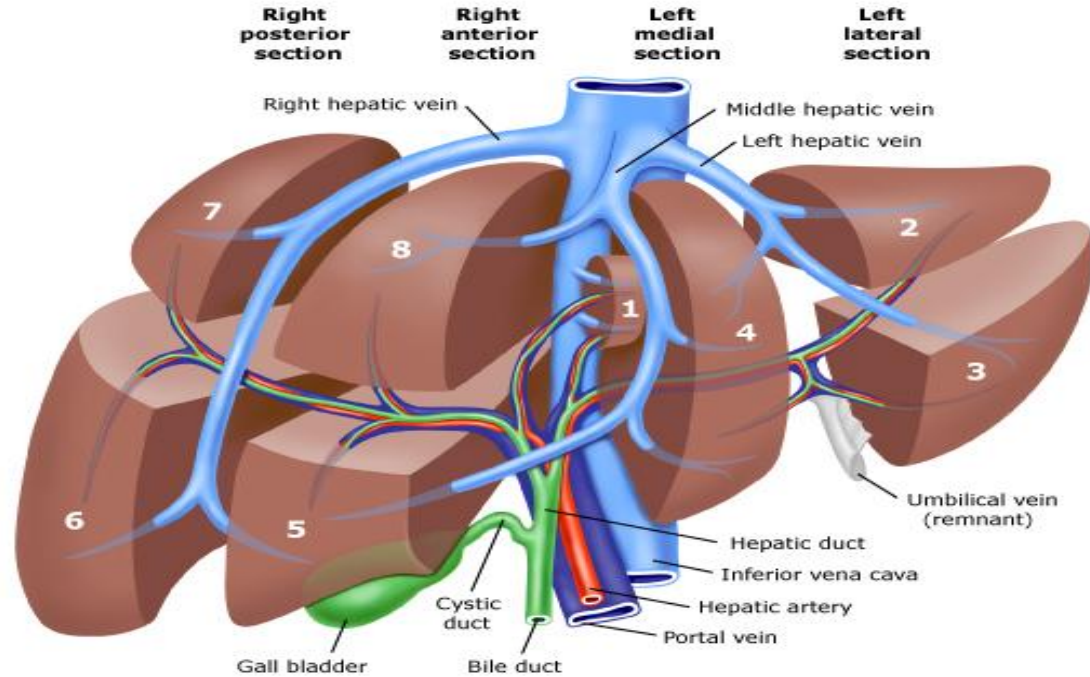
Select **File** → **Exit** to close the Brain Scene, and exit Slicer



Part 3:

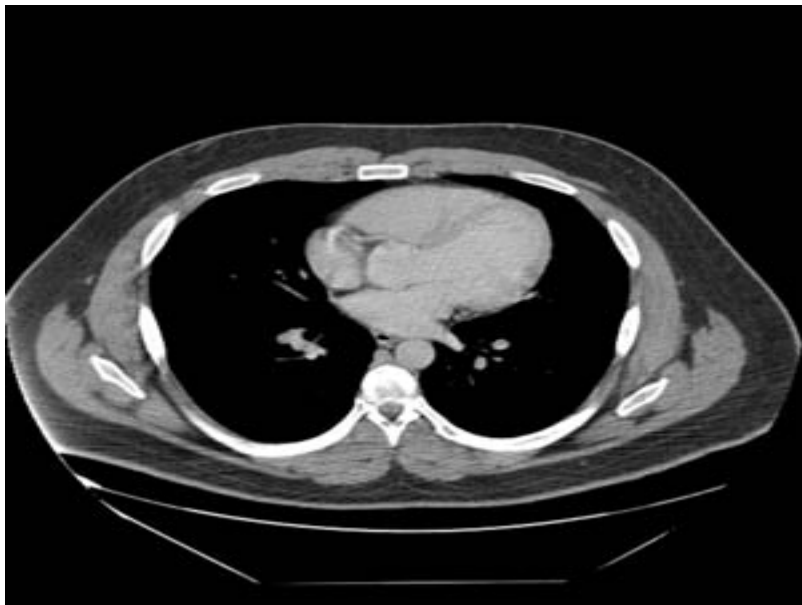
Interactive 3D Visualization of the segments of the liver

Anatomy of the liver





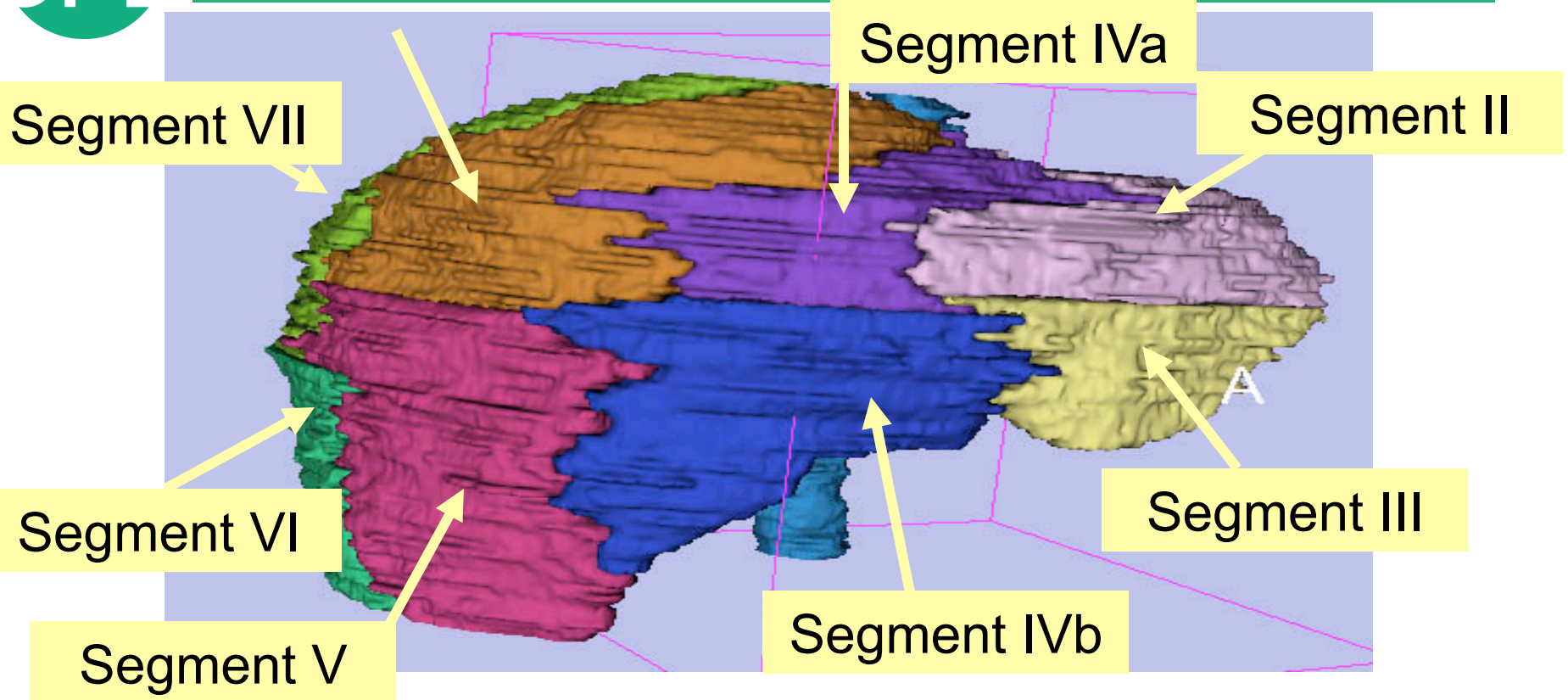
Liver dataset



The liver dataset is a contrast-enhanced CT abdominal scan of a healthy 36 year-old male.

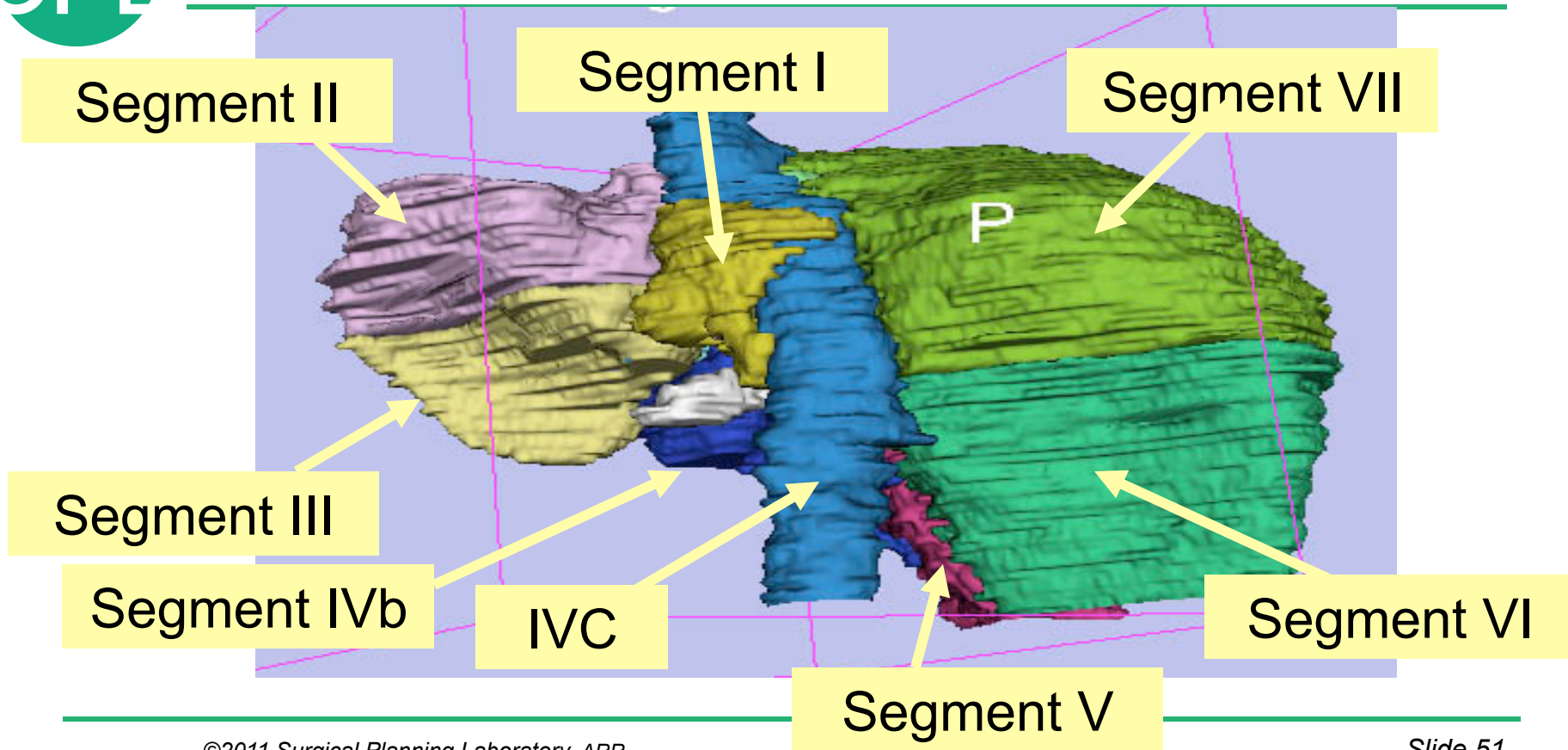


3D segments of the liver



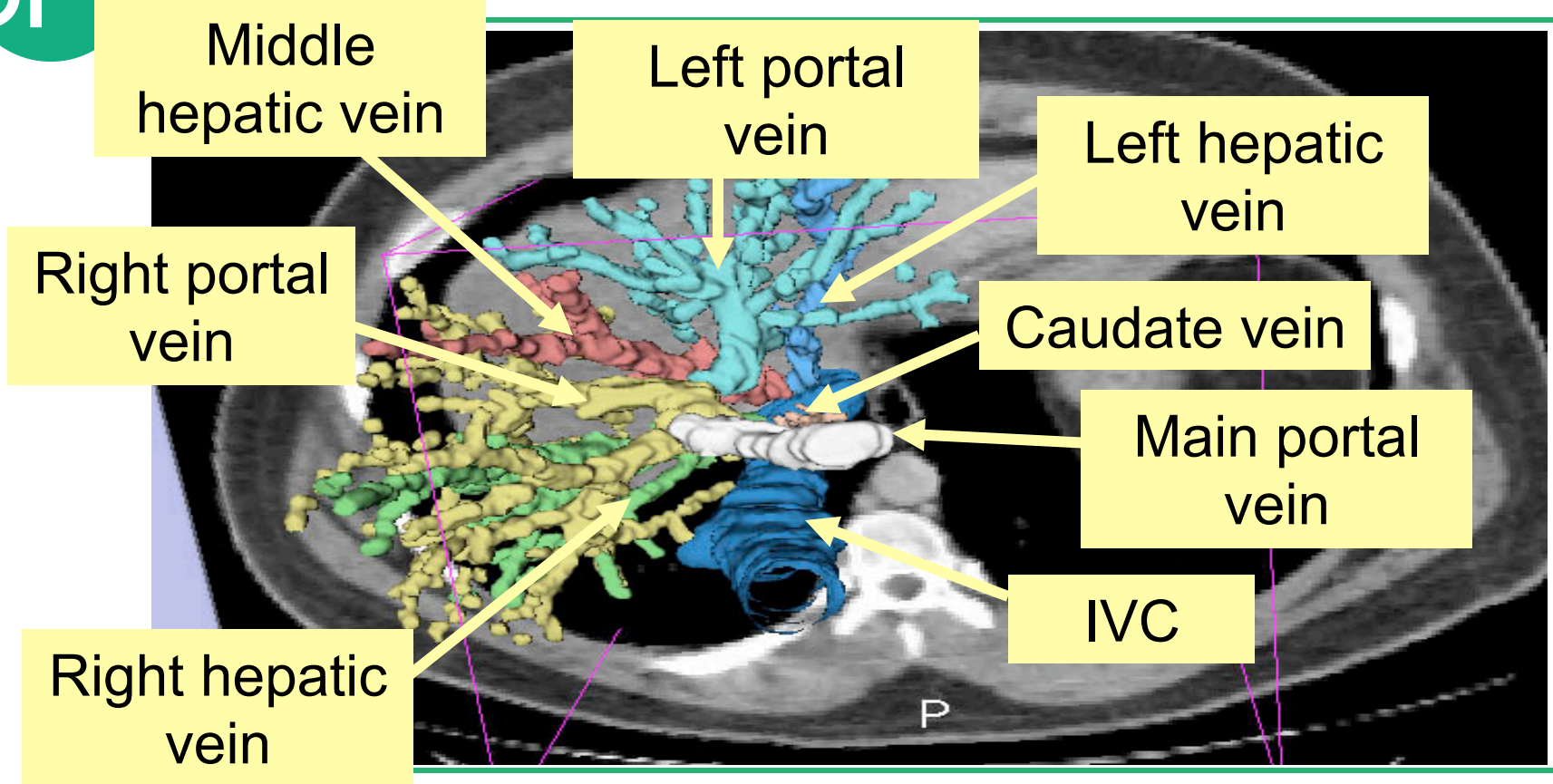


3D segments of the liver





Liver vasculature



Middle hepatic vein

Left portal vein

Left hepatic vein

Right portal vein

Caudate vein

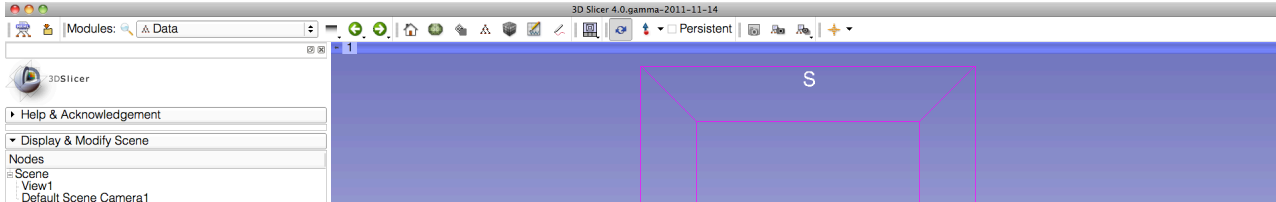
Main portal vein

Right hepatic vein

IVC




Loading the Liver Scene



Select **File** → **Load Scene** from the main menu

Load the file **Scene-Liver.mrml** located in:

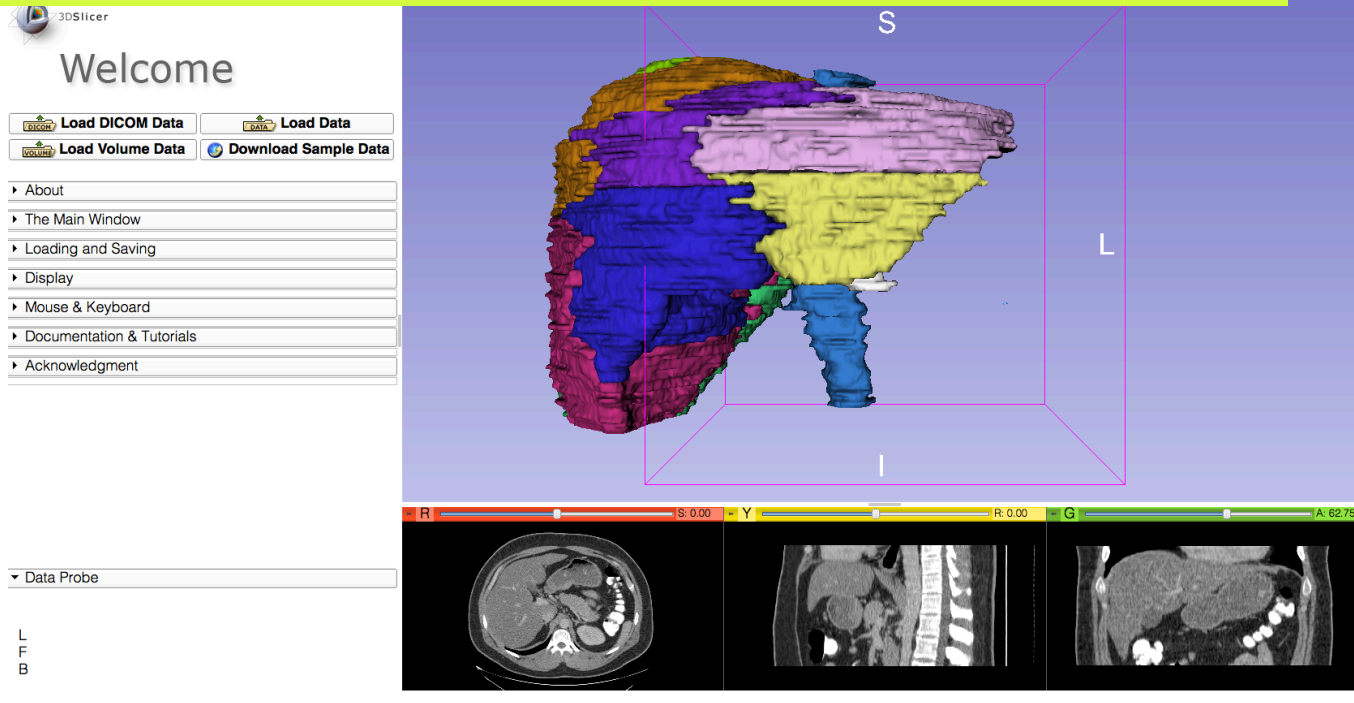
C:\Documents and Settings\Administrator\Desktop\3D\LiverData





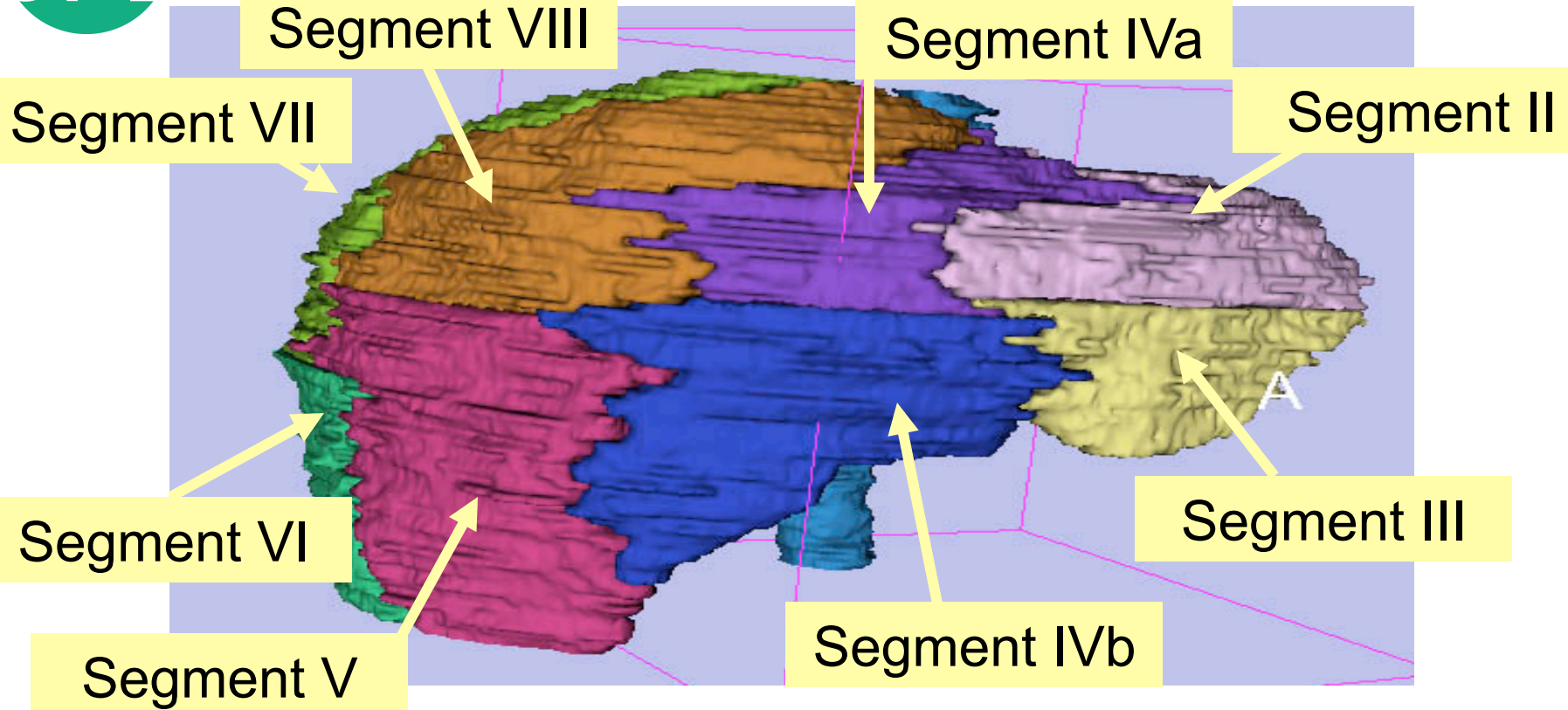
Liver Segments Scene

The elements of the scene appear in the Viewer



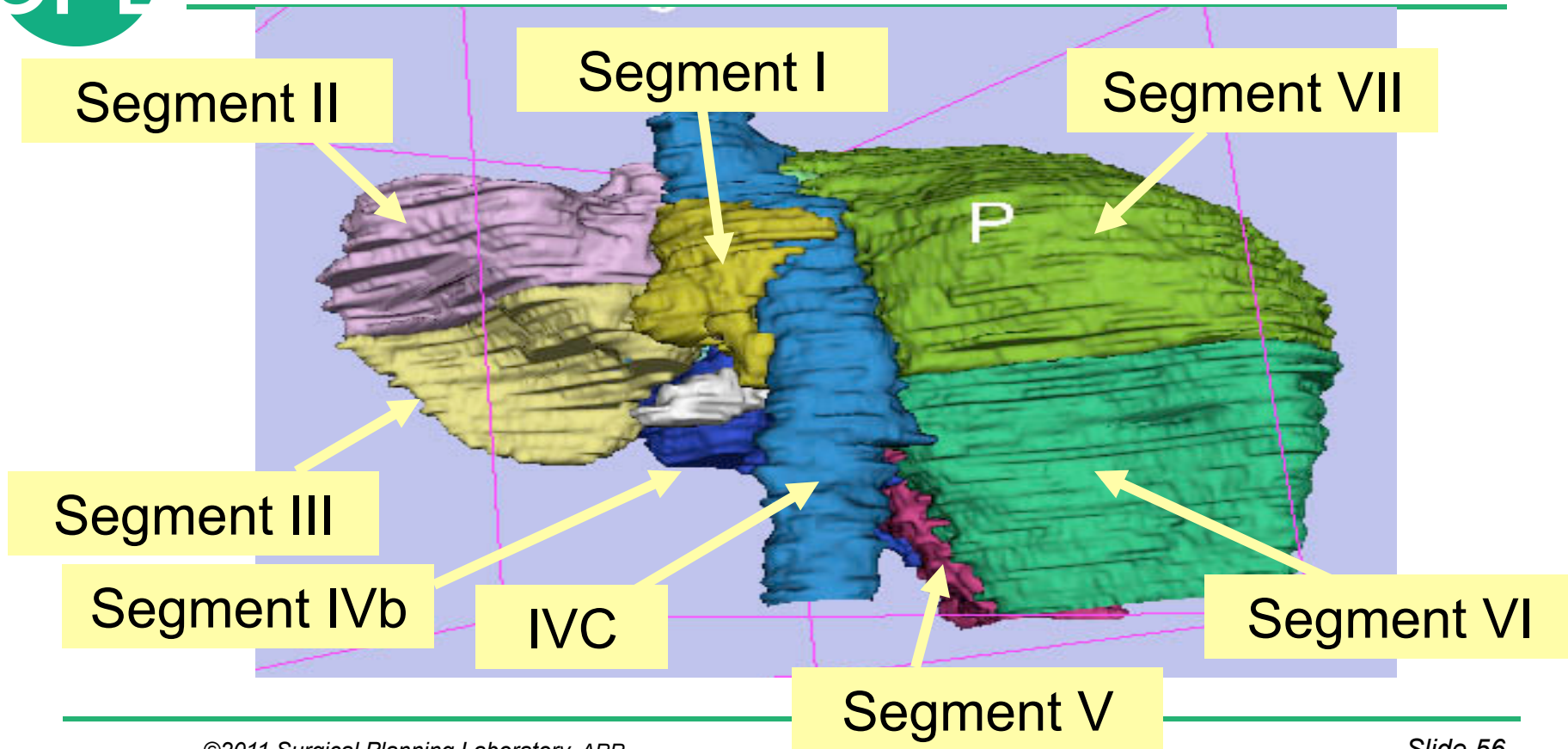


3D models of the liver



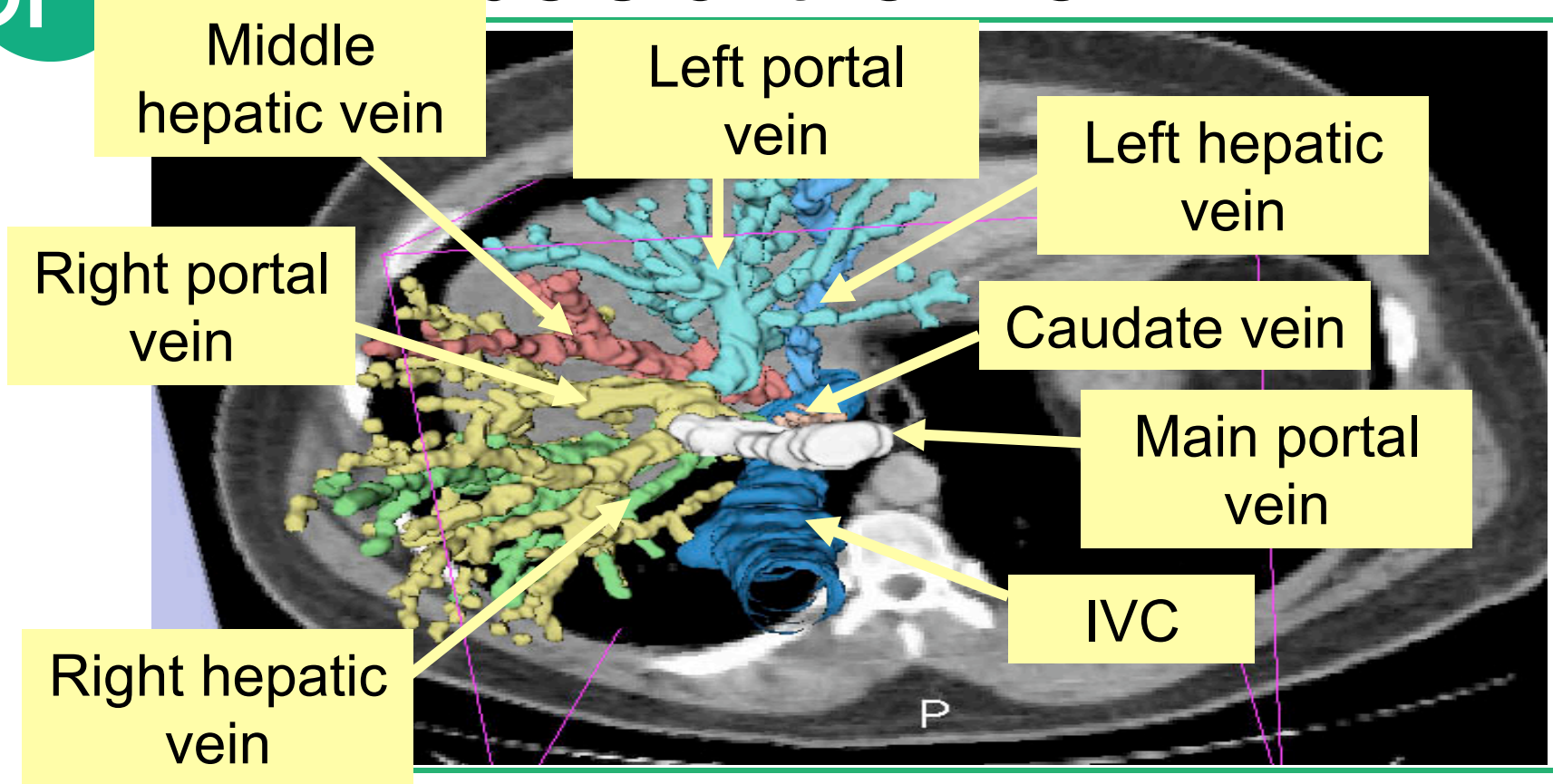


3D models of the liver





3D models of the liver



Middle hepatic vein

Left portal vein

Left hepatic vein

Right portal vein

Caudate vein

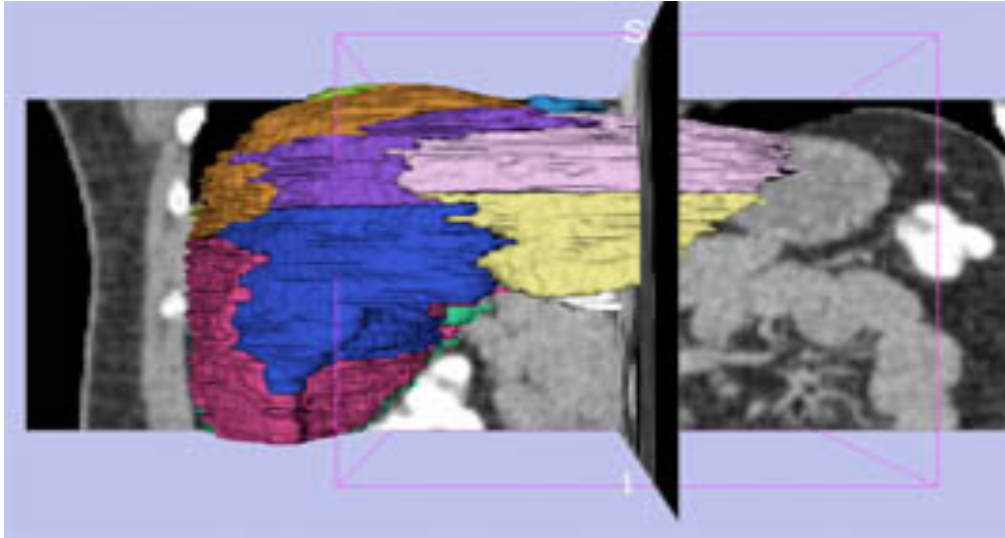
Main portal vein

Right hepatic vein

IVC



3D Exploration of Liver Segments

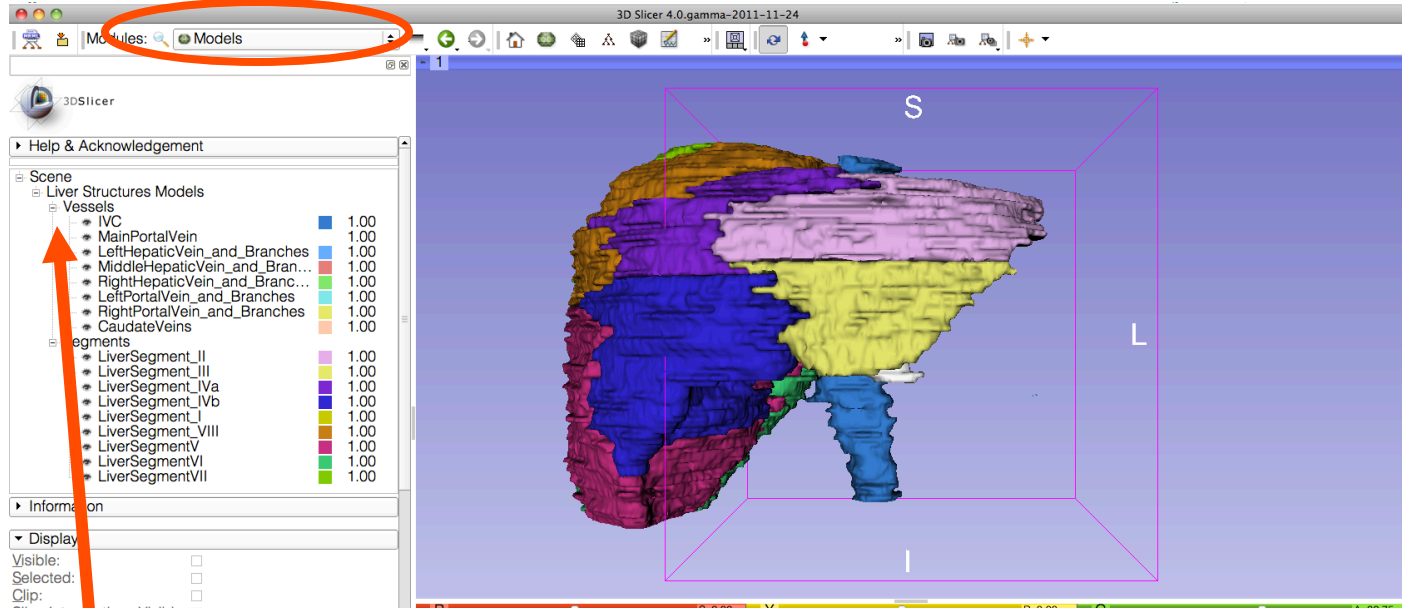


Example:

What organ abuts the left-most margin of segment II in this patient ?



3D Exploration of Liver Segments

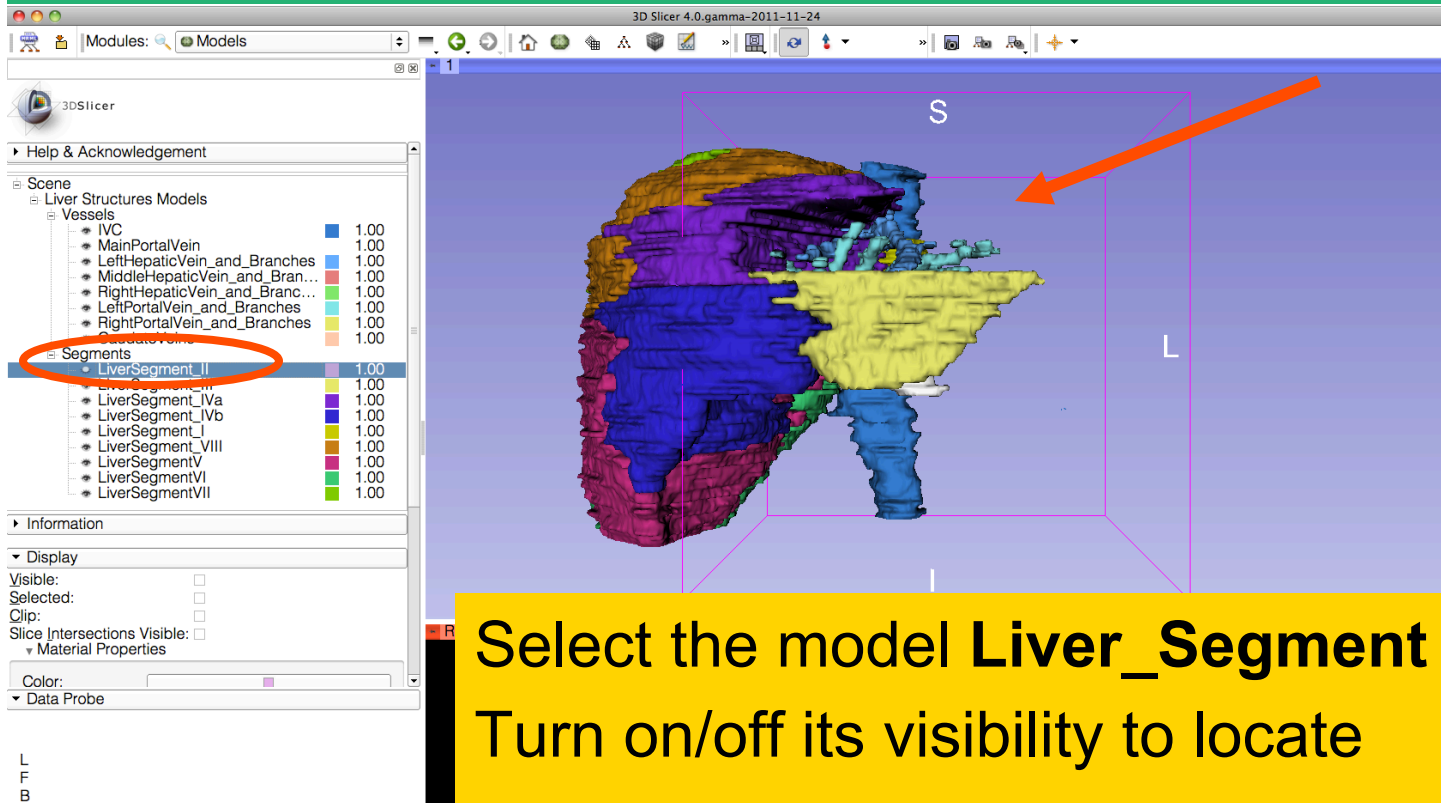


Select the module **Models**

Click on the Liver Structures Models Hierarchy



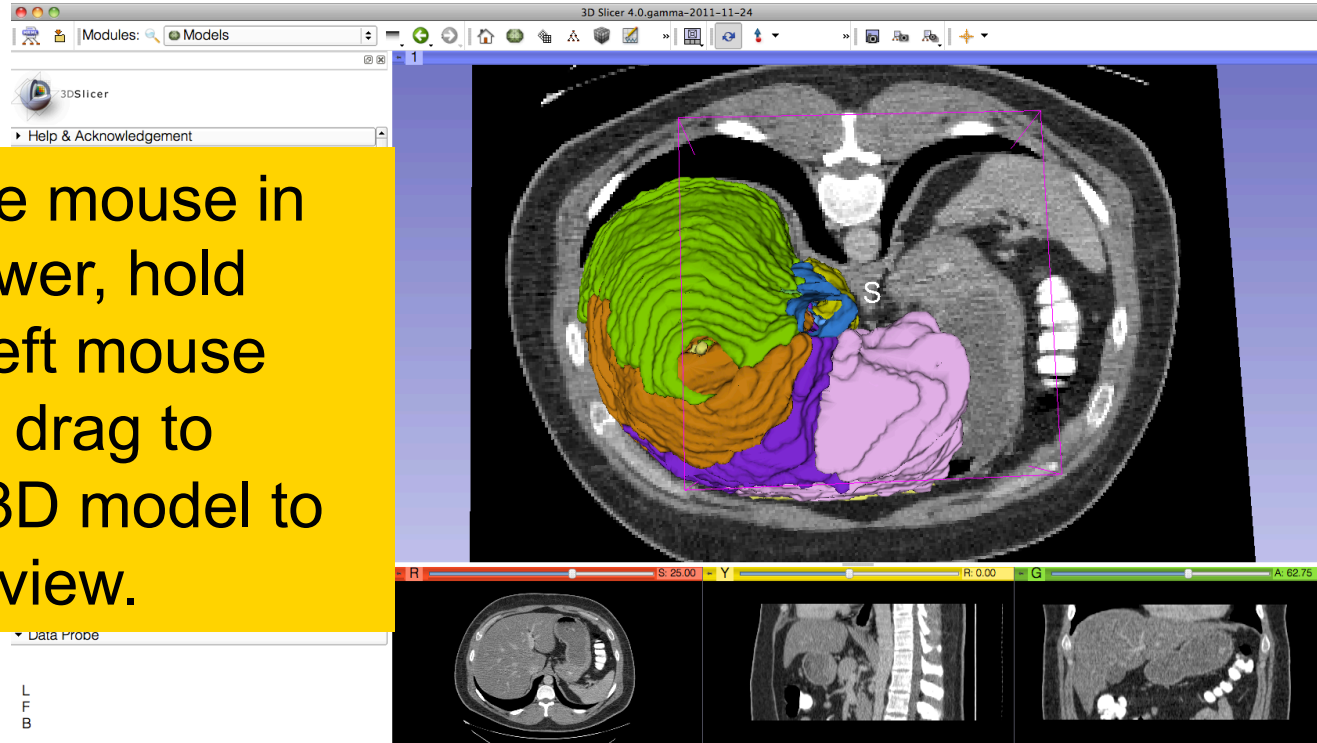
3D Exploration of Liver Segments





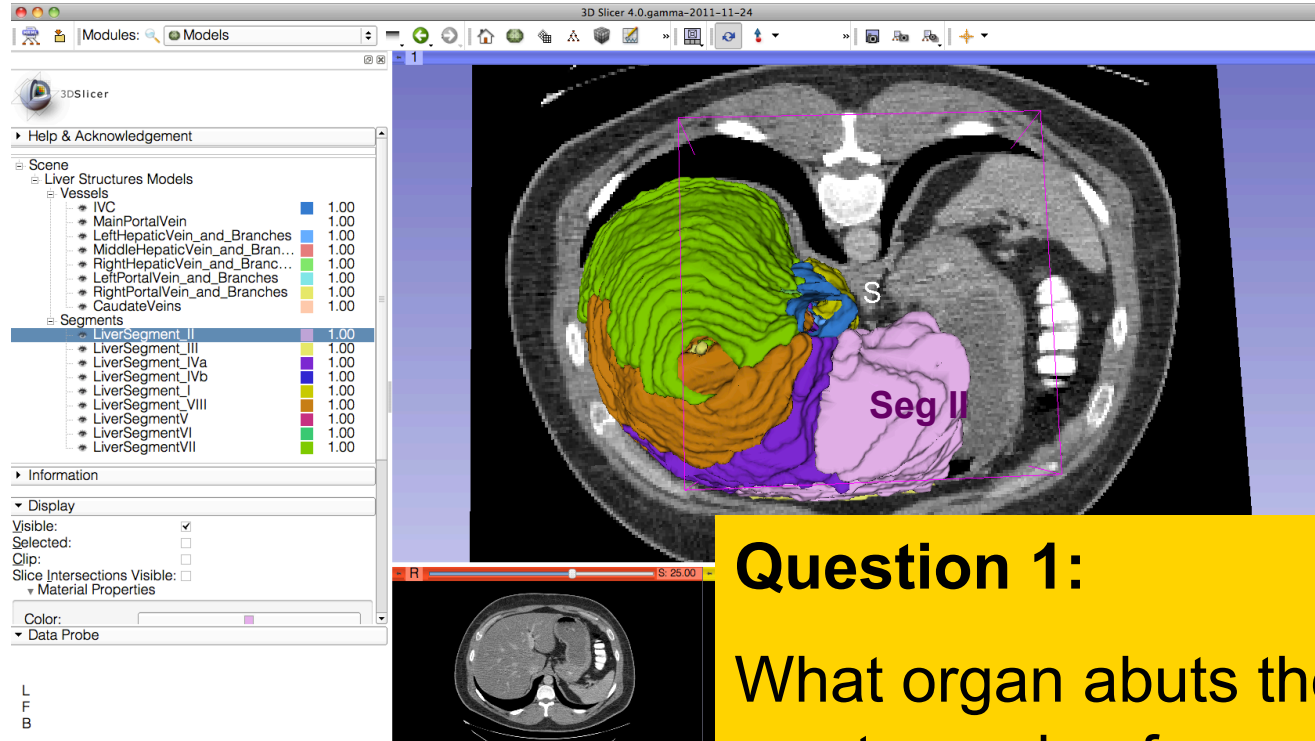
3D Exploration of Liver Segments

Position the mouse in the 3D Viewer, hold down the left mouse button and drag to orient the 3D model to a superior view.





3D Exploration of Liver Segments



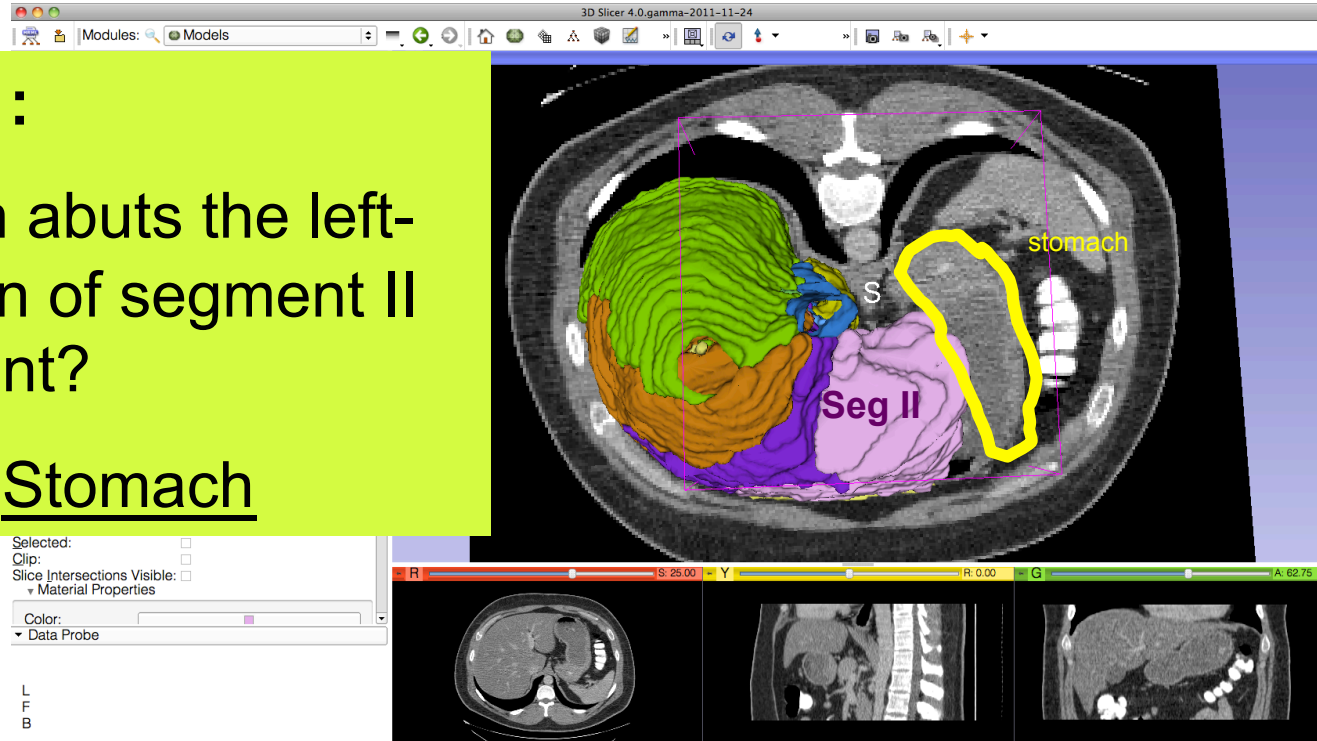


3D Exploration of Liver Segments

Question 1:

What organ abuts the left-most margin of segment II in this patient?

Answer 1: Stomach

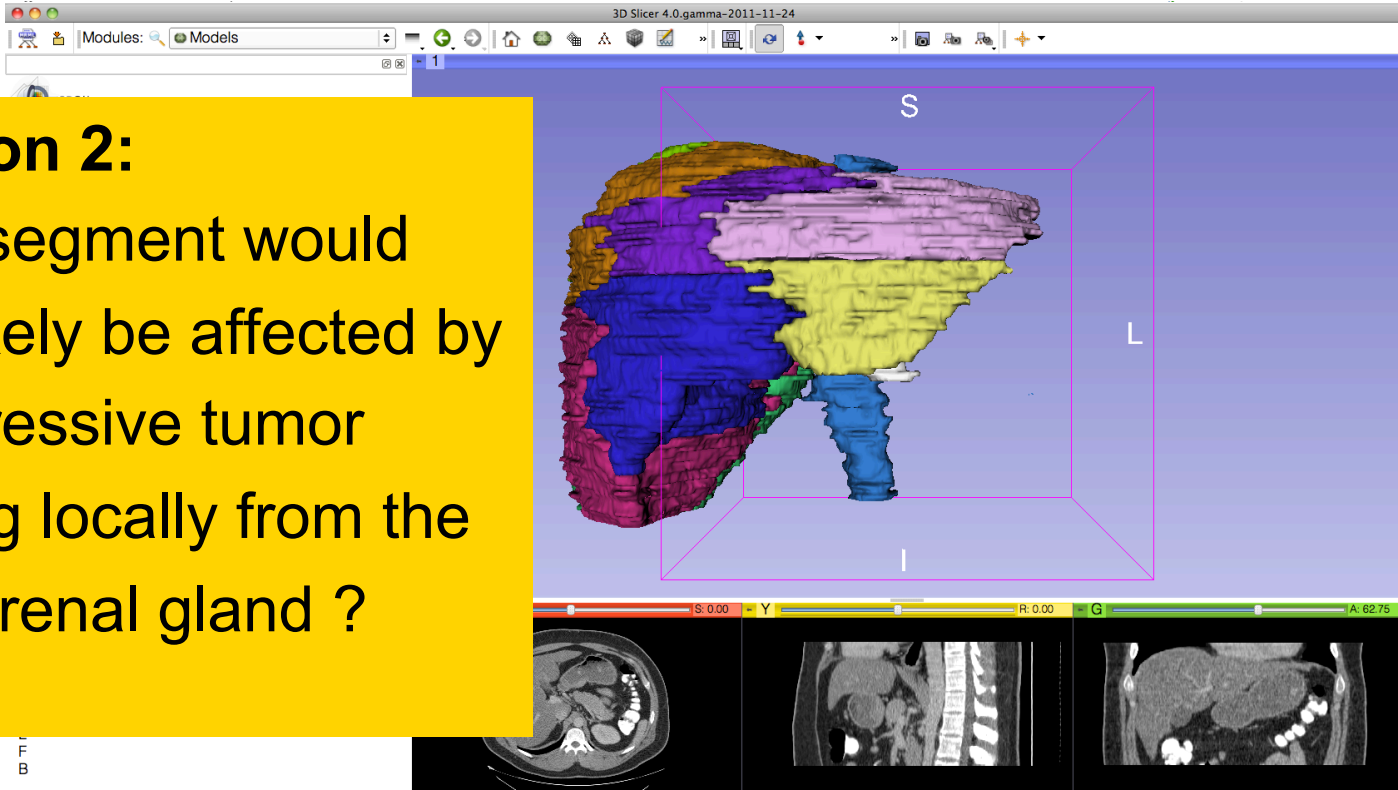




3D Exploration of Liver Segments

Question 2:

Which segment would most likely be affected by an aggressive tumor invading locally from the right adrenal gland ?



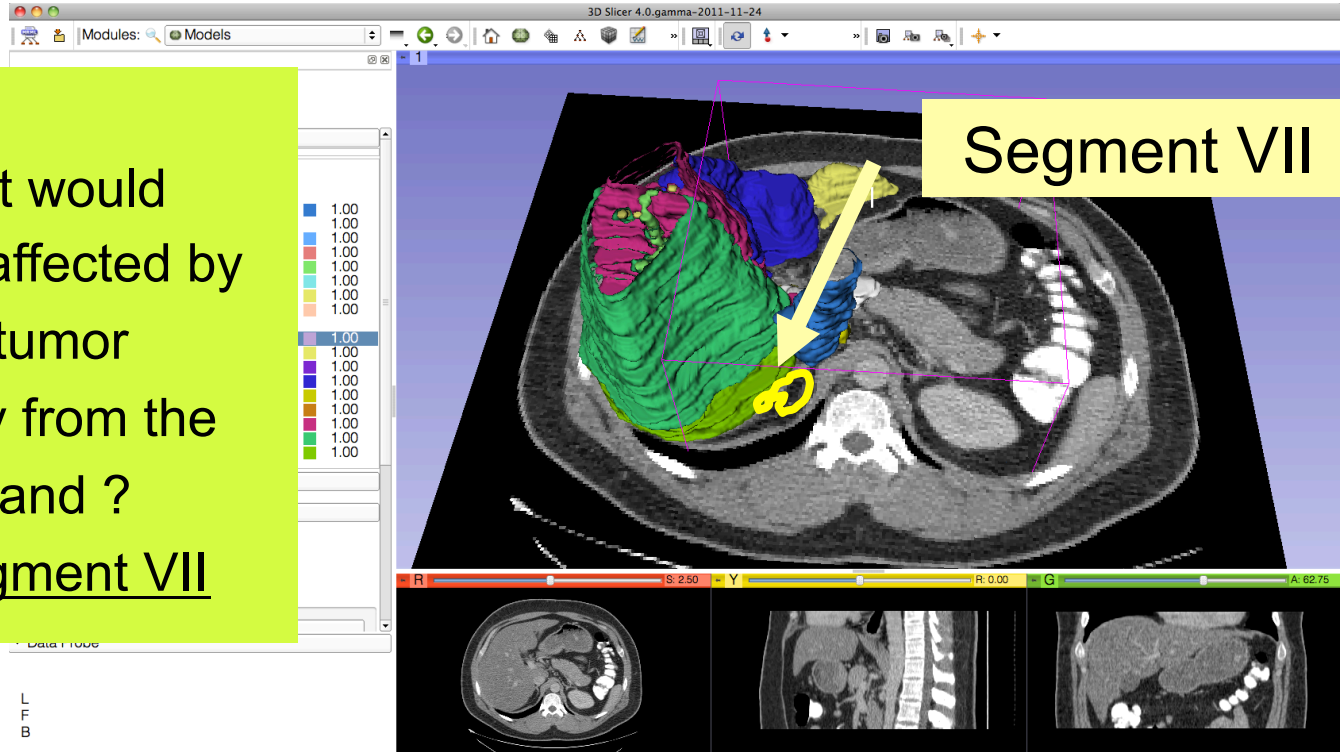

3D Exploration of Liver Segments

Question 2:

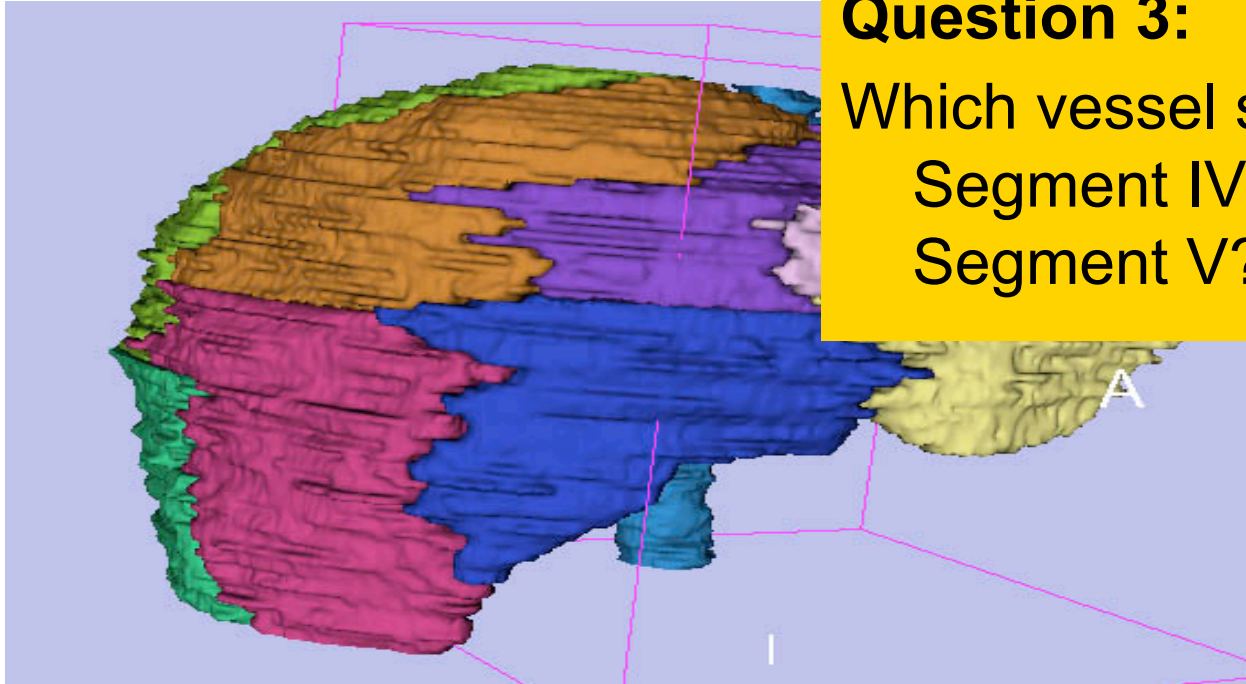Which segment would most likely be affected by an aggressive tumor invading locally from the right adrenal gland ?

Answer 2: Segment VII





3D Exploration of Liver Segments

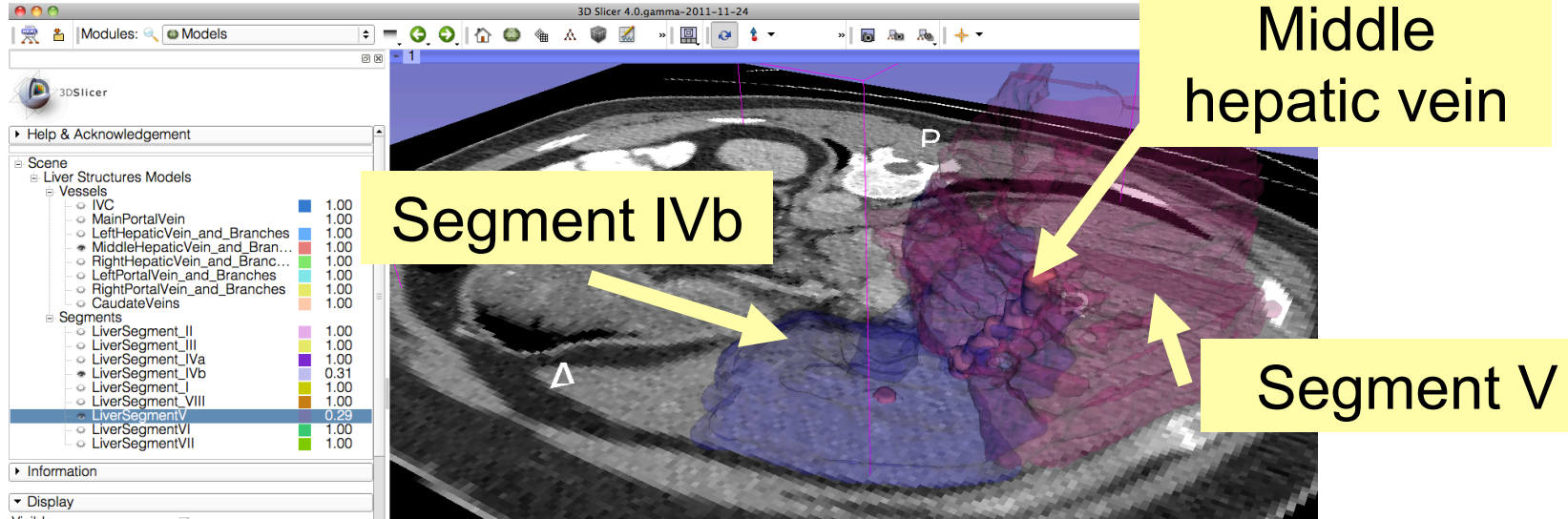


Question 3:

Which vessel separates Segment IVb and Segment V?



Middle Hepatic Vein



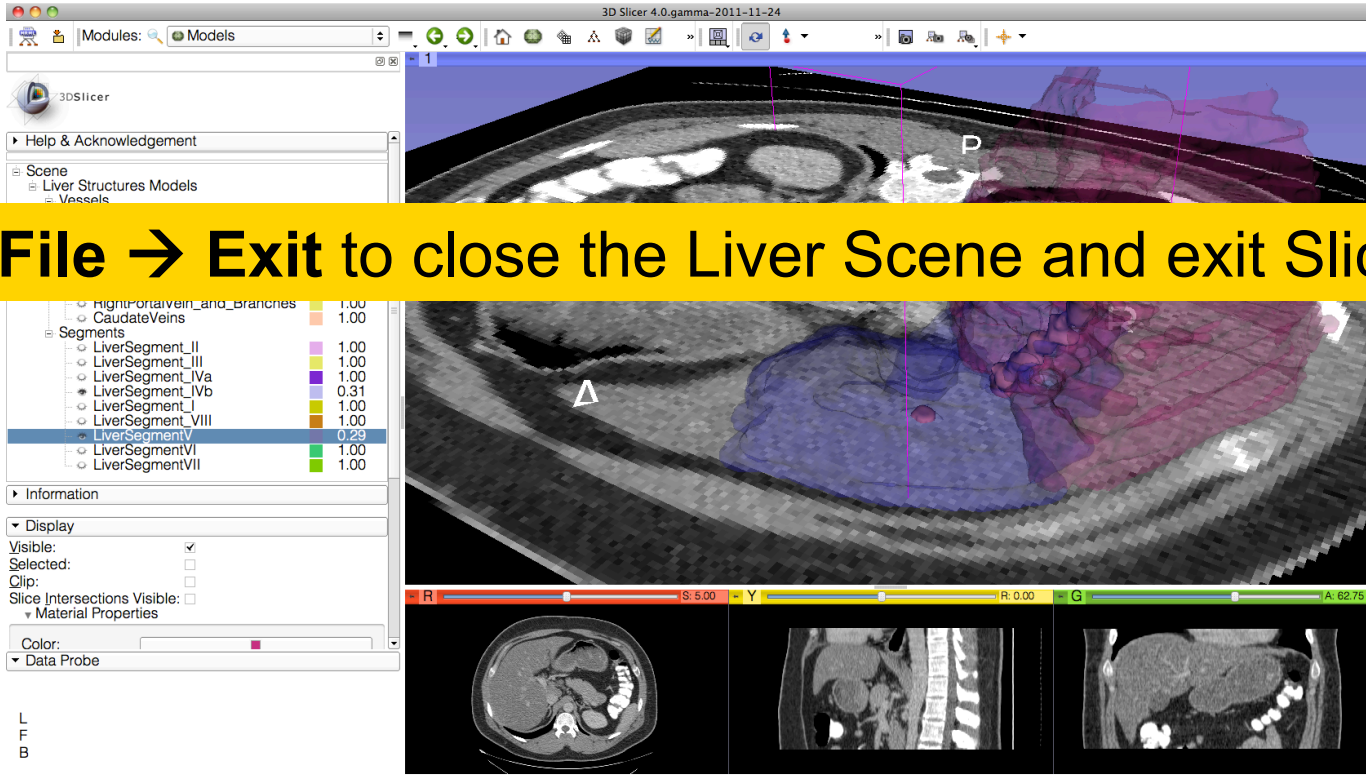Question 3:

Which vessel separates Segment IVb and Segment V?

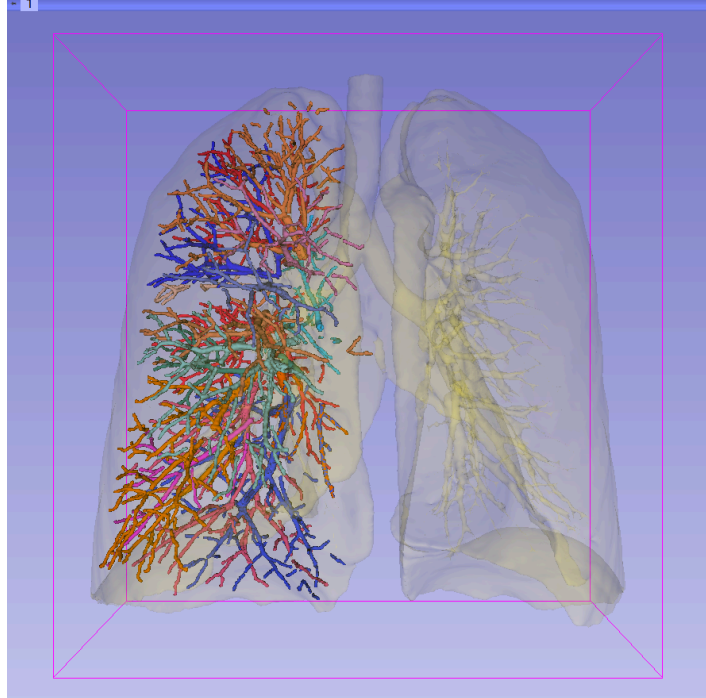
Answer 3: The middle hepatic vein



Closing the Liver Scene



Select **File** → **Exit** to close the Liver Scene and exit Slicer

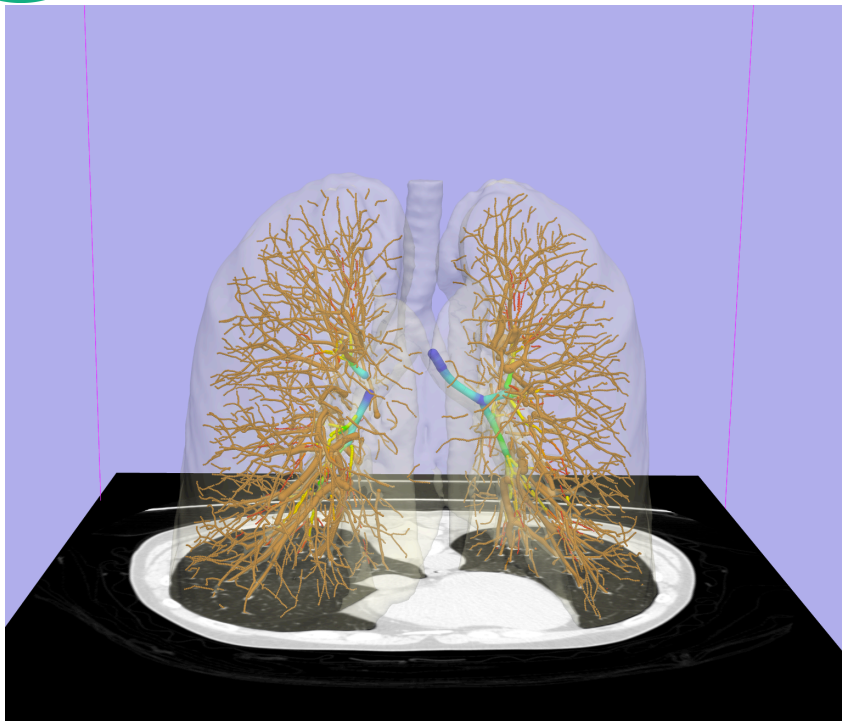


Part 4:

Interactive 3D Visualization
of the segments of the lungs



Segments of the lung



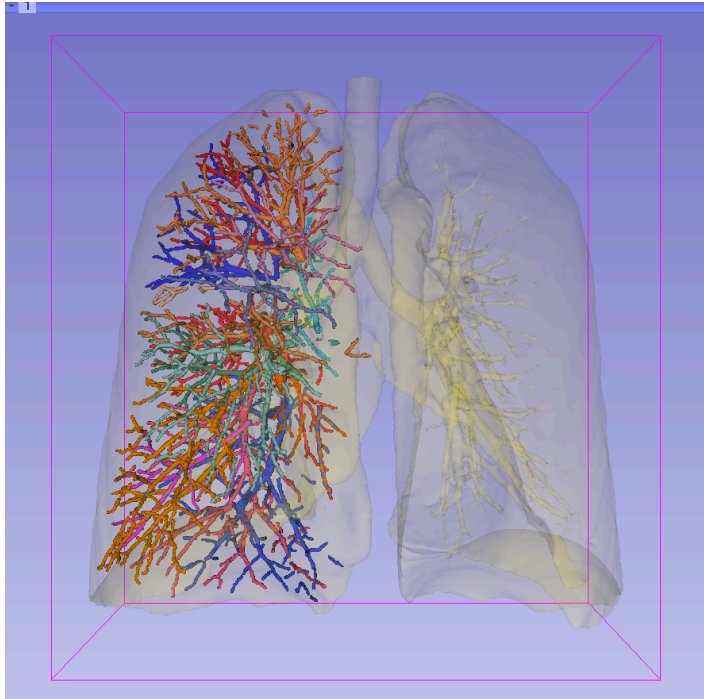
Segmentation and 3D surface reconstruction of the lung and pulmonary vessels

Acknowledgment:

Segmentation of the lung surface and vasculature:
Raul San Jose Estepar, Ph.D., George Washko, M.D., Ed Silverman, M.D. and James Ross, MSc. Brigham and Women's Hospital, Boston, MA



Segments of the lung

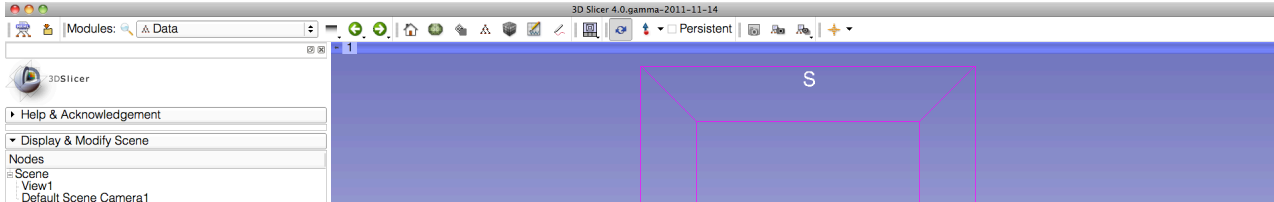


3D parcellation of arteries and veins from original model of pulmonary vessels
(Kitt Shaffer, M.D., Ph.D. - Sonia Pujol, Ph.D.)

- Right Upper Lobe (RUL)
 - RUL Pulmonary Vein
 - RUL Anterior Segment
 - RUL Apical Segment
 - RUL Posterior Segment
- Right Middle Lobe (RML)
 - RML Pulmonary Vein 1 & 2
 - RML Lateral Segment
 - RML Medial Segment
- Right Lower Lobe (RLL)
 - RLL Pulmonary Vein 1,2,3
 - RLL Anterior Basal Segment
 - RLL Medial Basal Segment
 - RLL Lateral Basal Segment
 - RLL Posterior Basal Segment




Loading the Lung Scene



Select **File** → **Load Scene** from the main menu

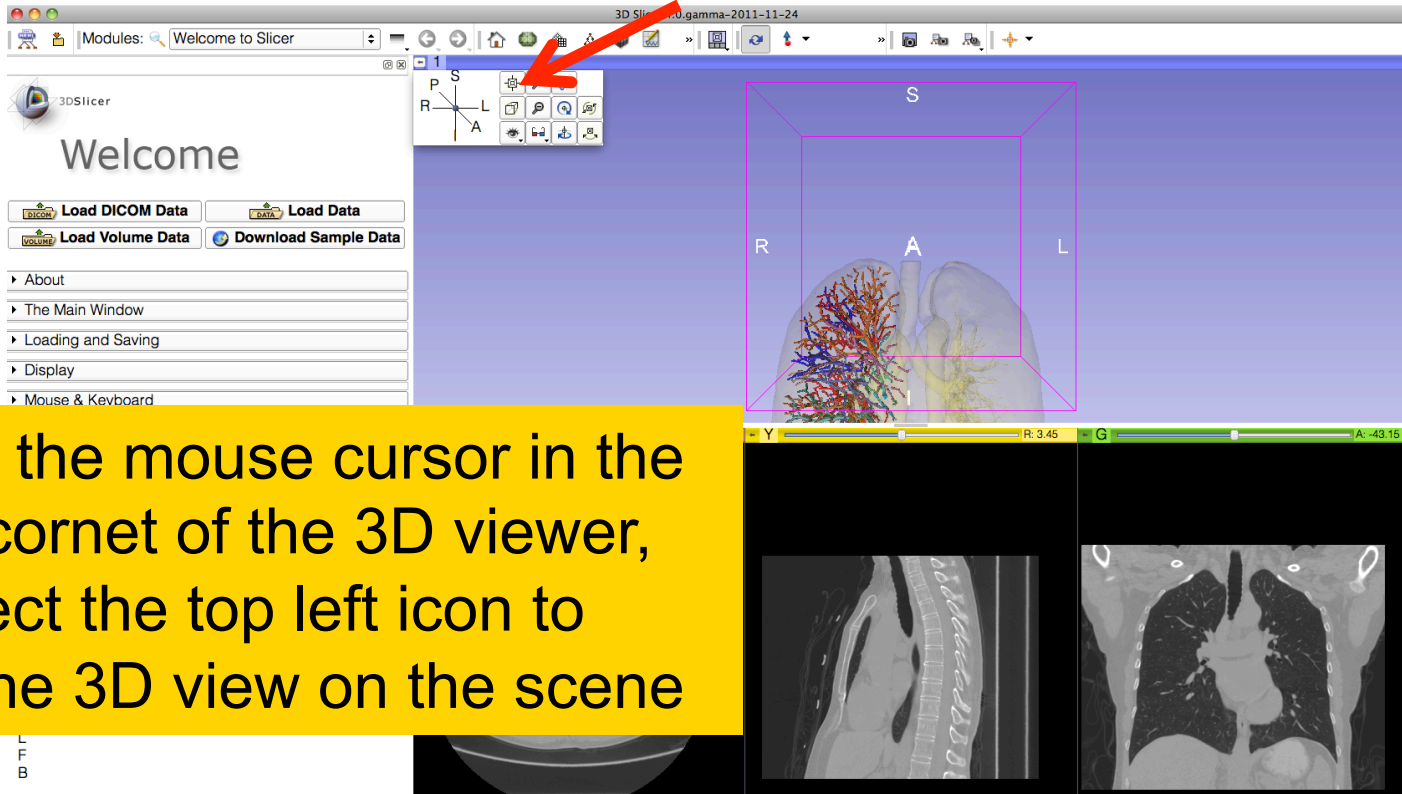
Load the file **LungSegment_Scene.mrml** located in:

C:\Documents and Settings\Administrator\Desktop\3D\LungData





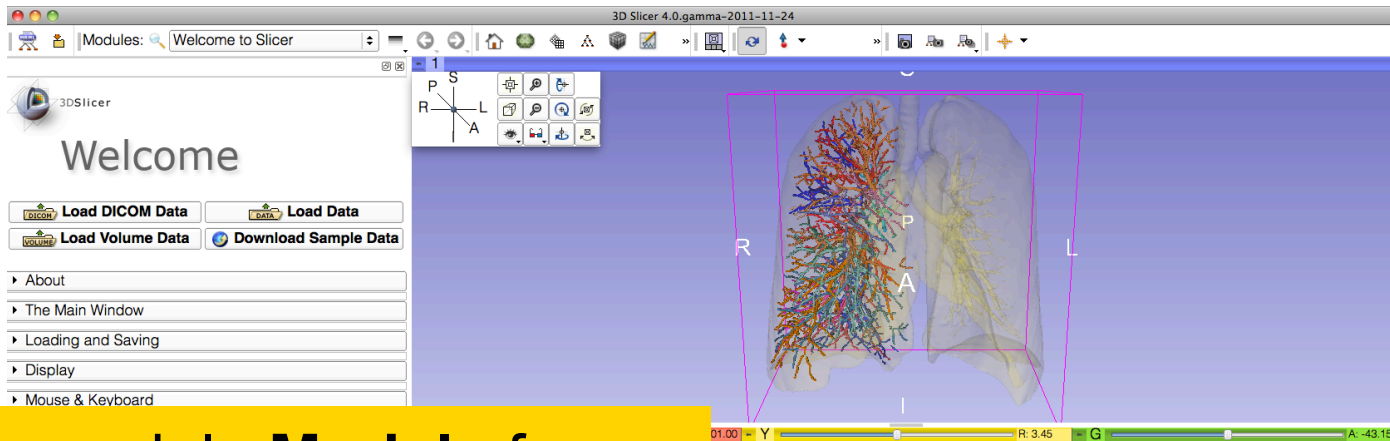
Loading the Lung Scene



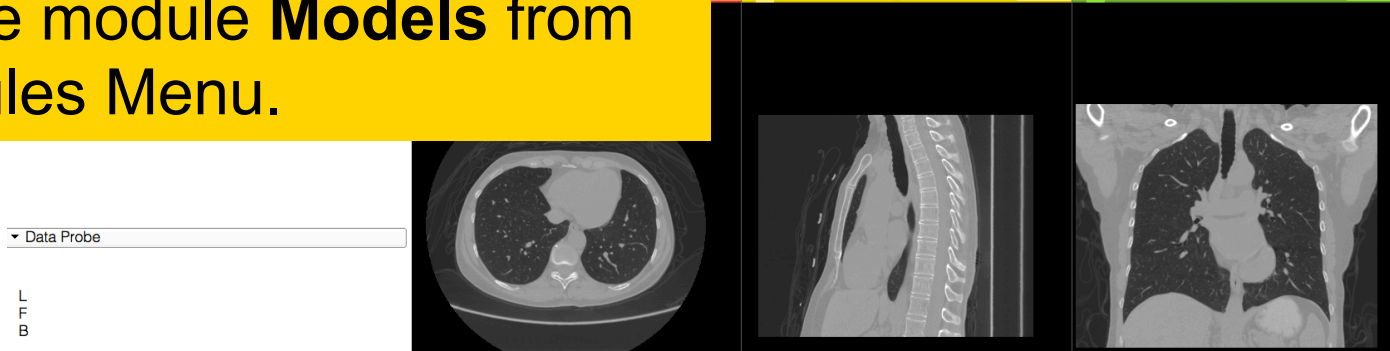
Position the mouse cursor in the top left corner of the 3D viewer, and select the top left icon to center the 3D view on the scene



Loading the Lung Scene

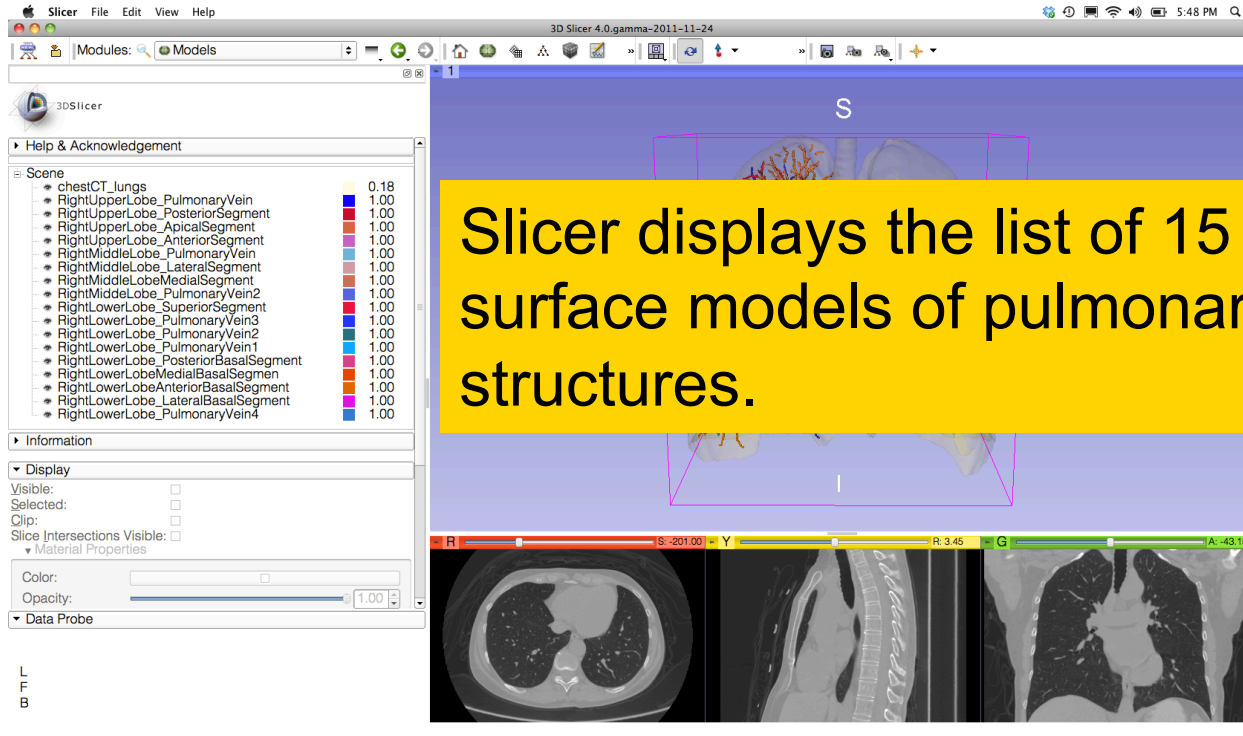

Select the module **Models** from the modules Menu.





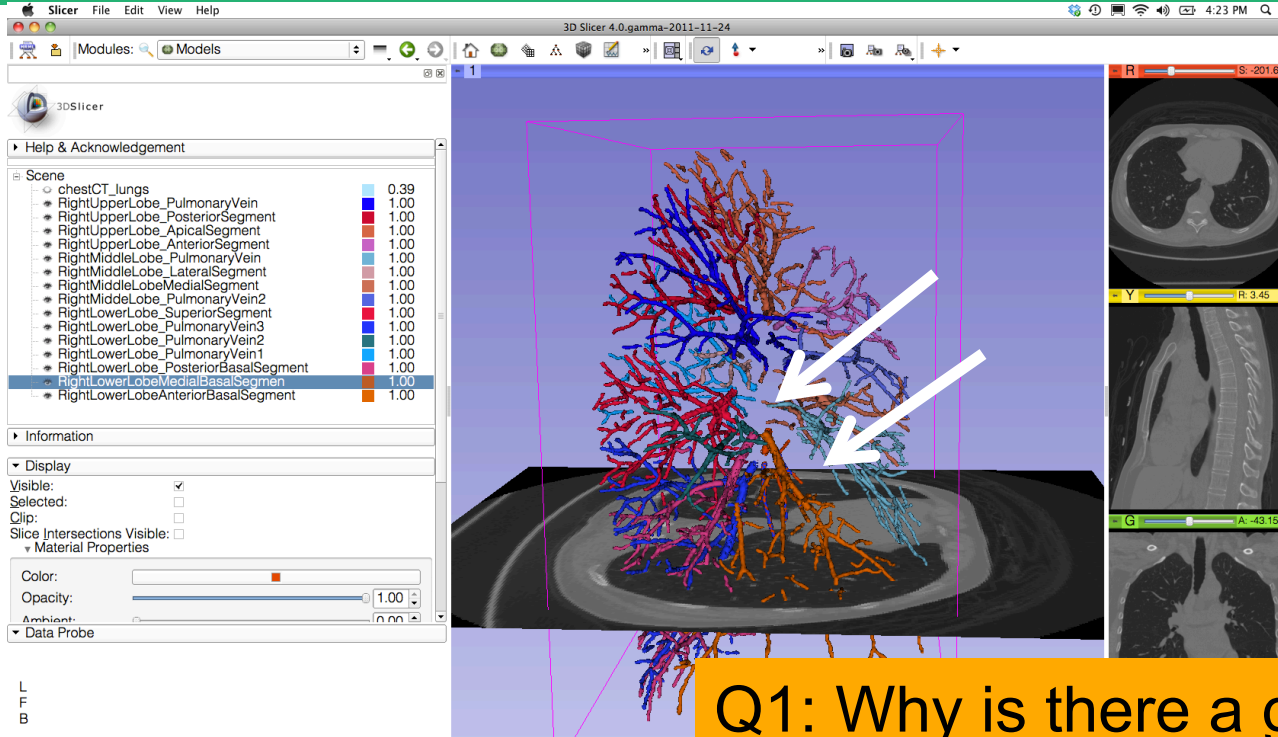
Lung Segments



Slicer displays the list of 15 surface models of pulmonary structures.



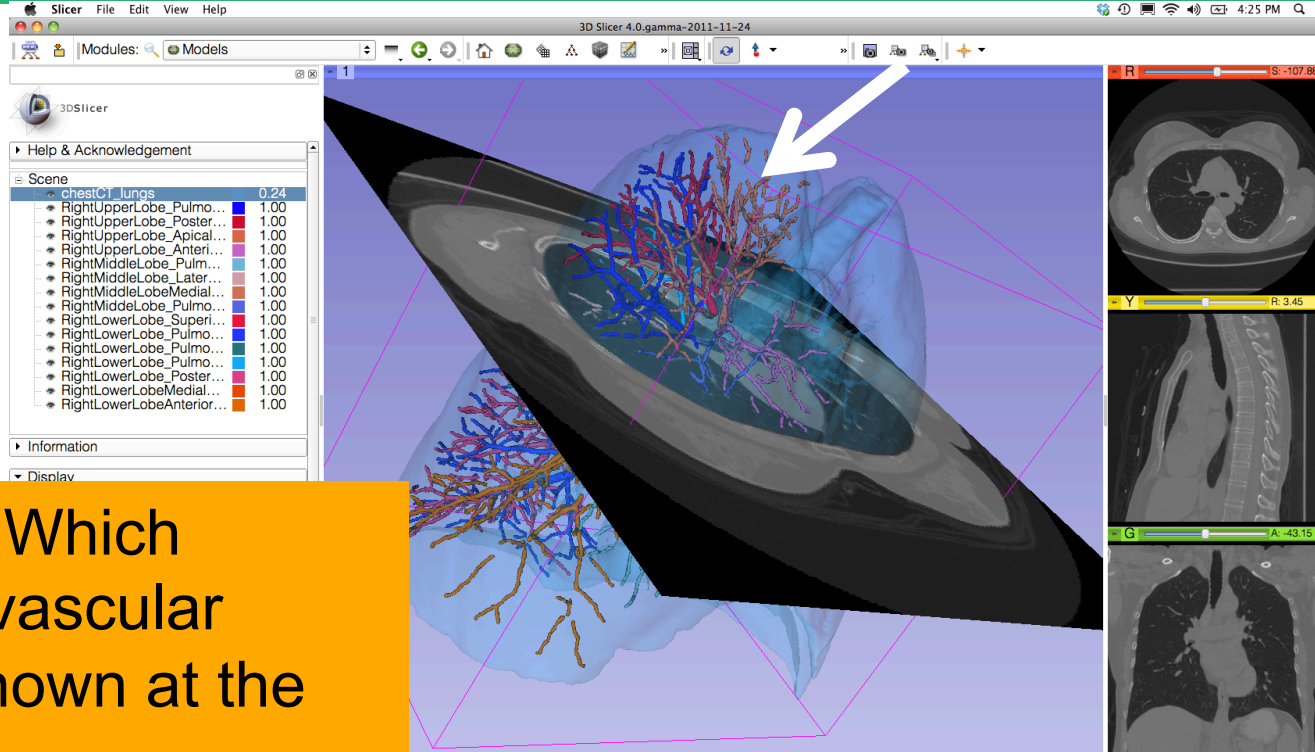
Lung Segments – Question 1



Q1: Why is there a gap in the vessels at the arrows?



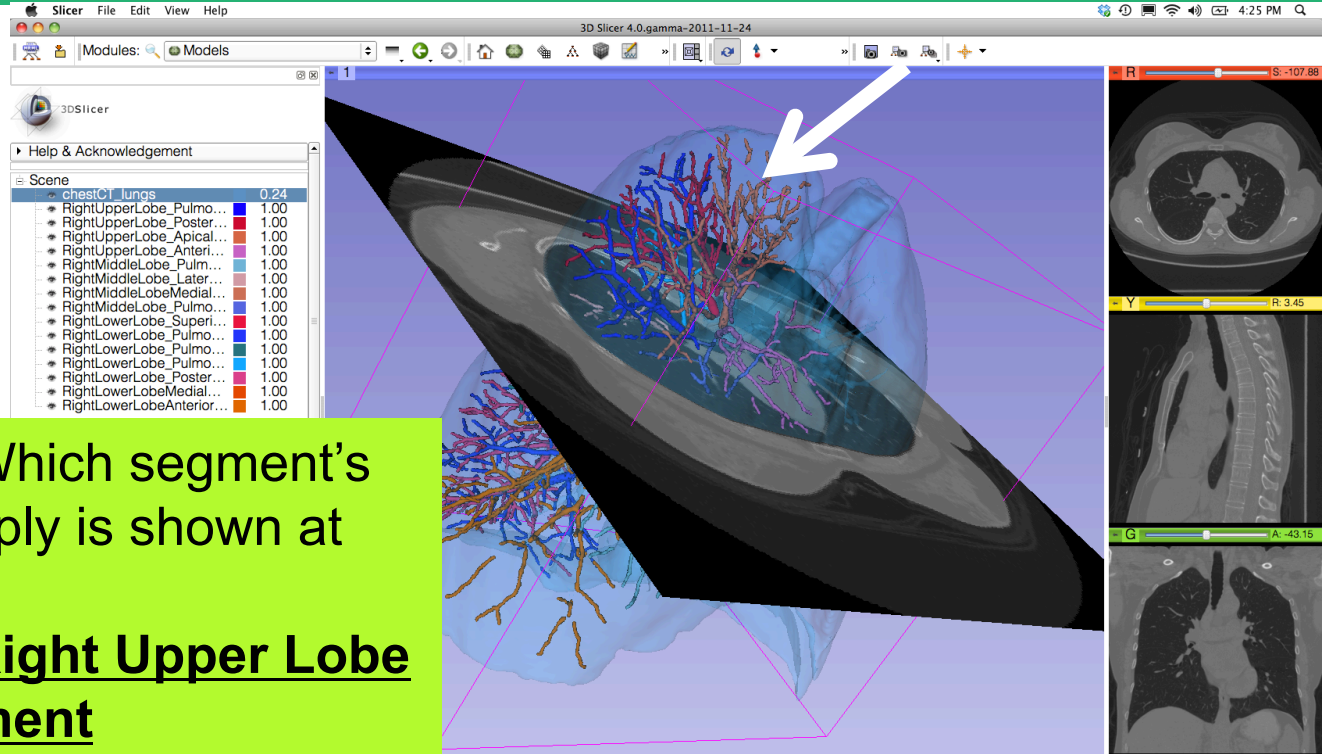
Lung Segments – Question 2



Question 2: Which segment's vascular supply is shown at the arrow?



Lung Segments – Question 2

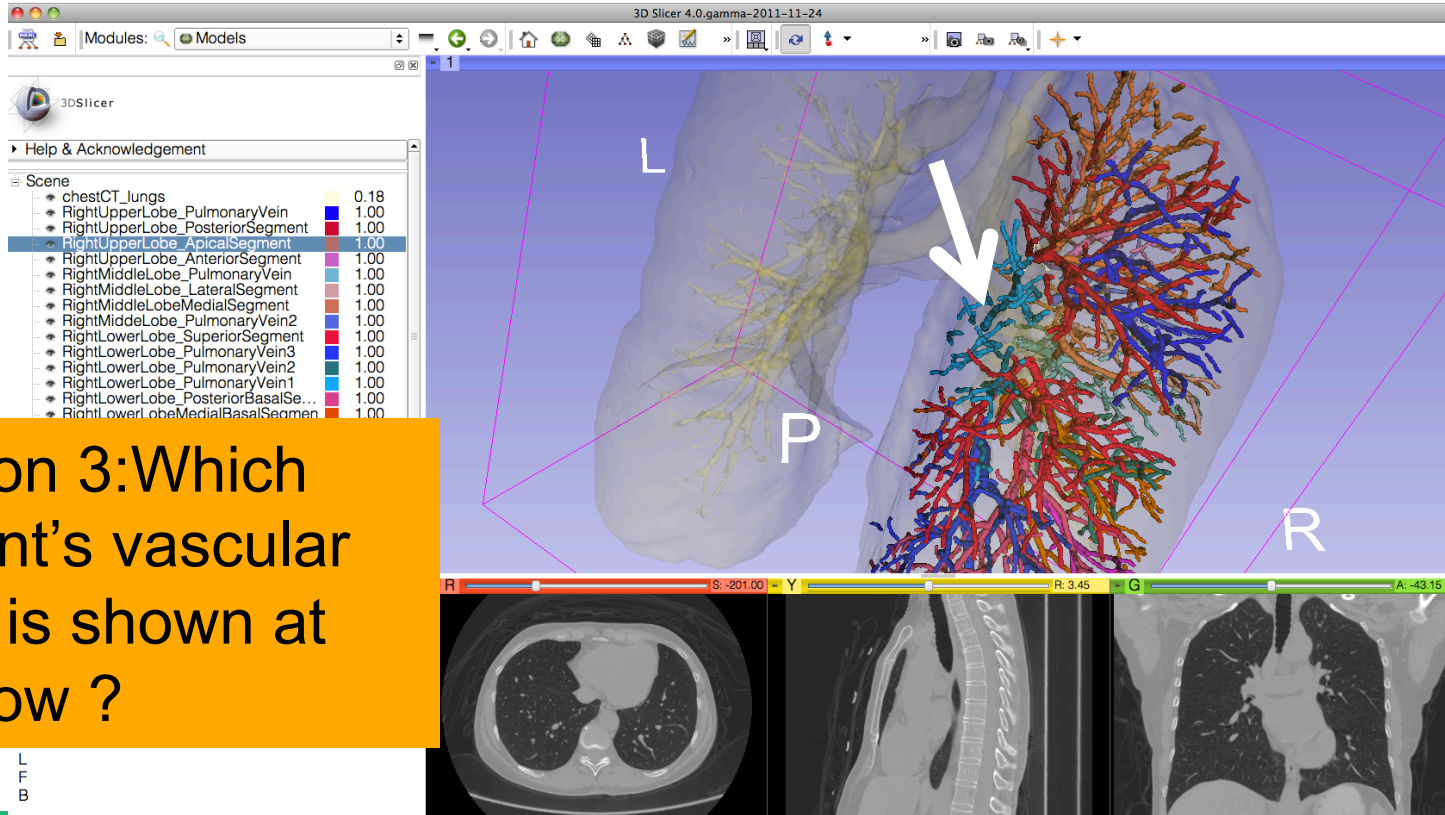


Question 2: Which segment's vascular supply is shown at the arrow?

Answer 2: Right Upper Lobe Apical Segment



Lung Segments – Question 3

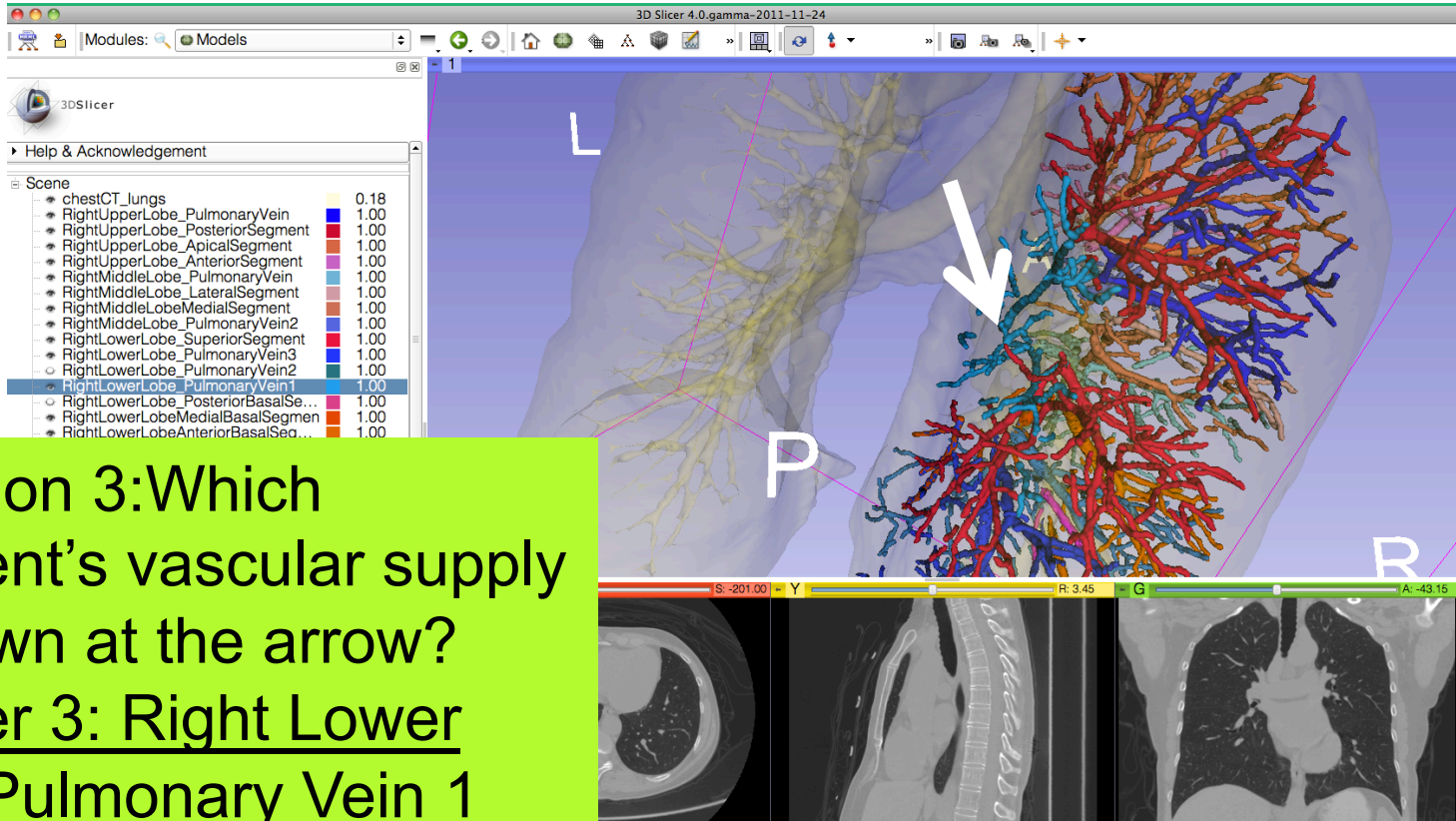


Question 3: Which segment's vascular supply is shown at the arrow ?

L
F
B



Lung Segments – Question 3



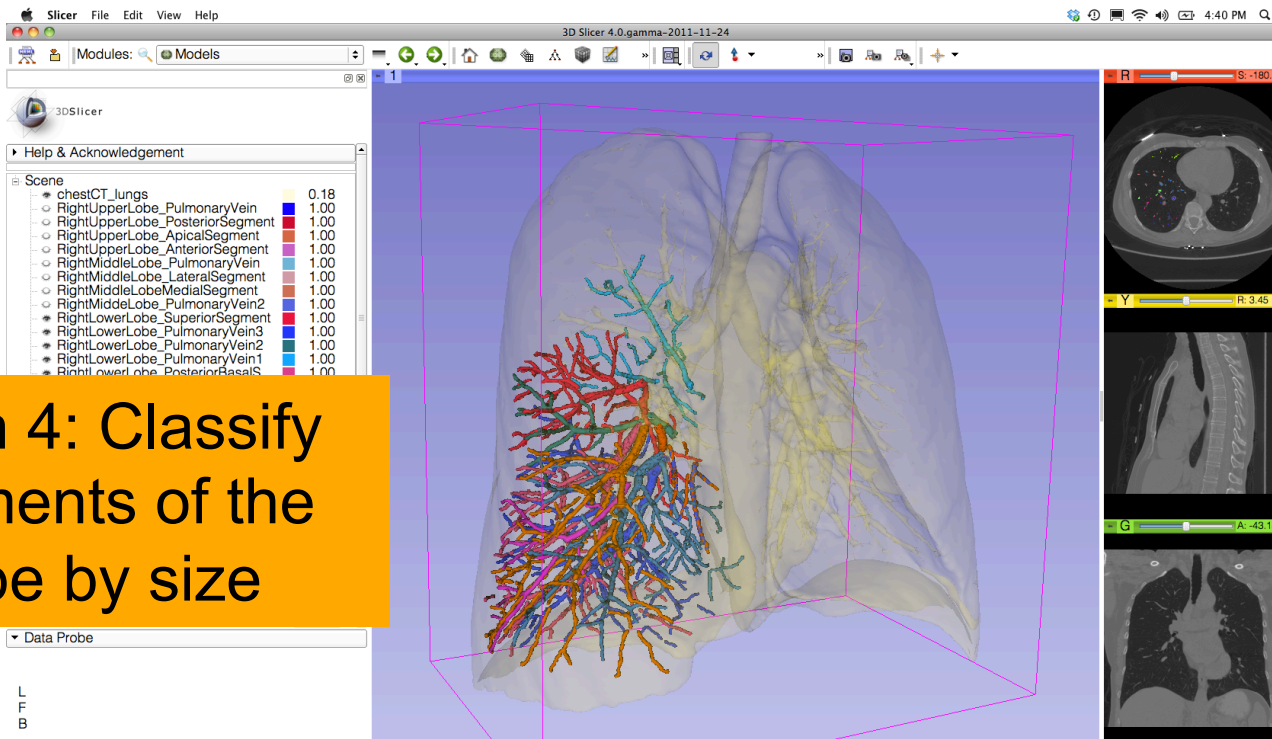
Question 3: Which segment's vascular supply is shown at the arrow?

Answer 3: Right Lower Lobe Pulmonary Vein 1



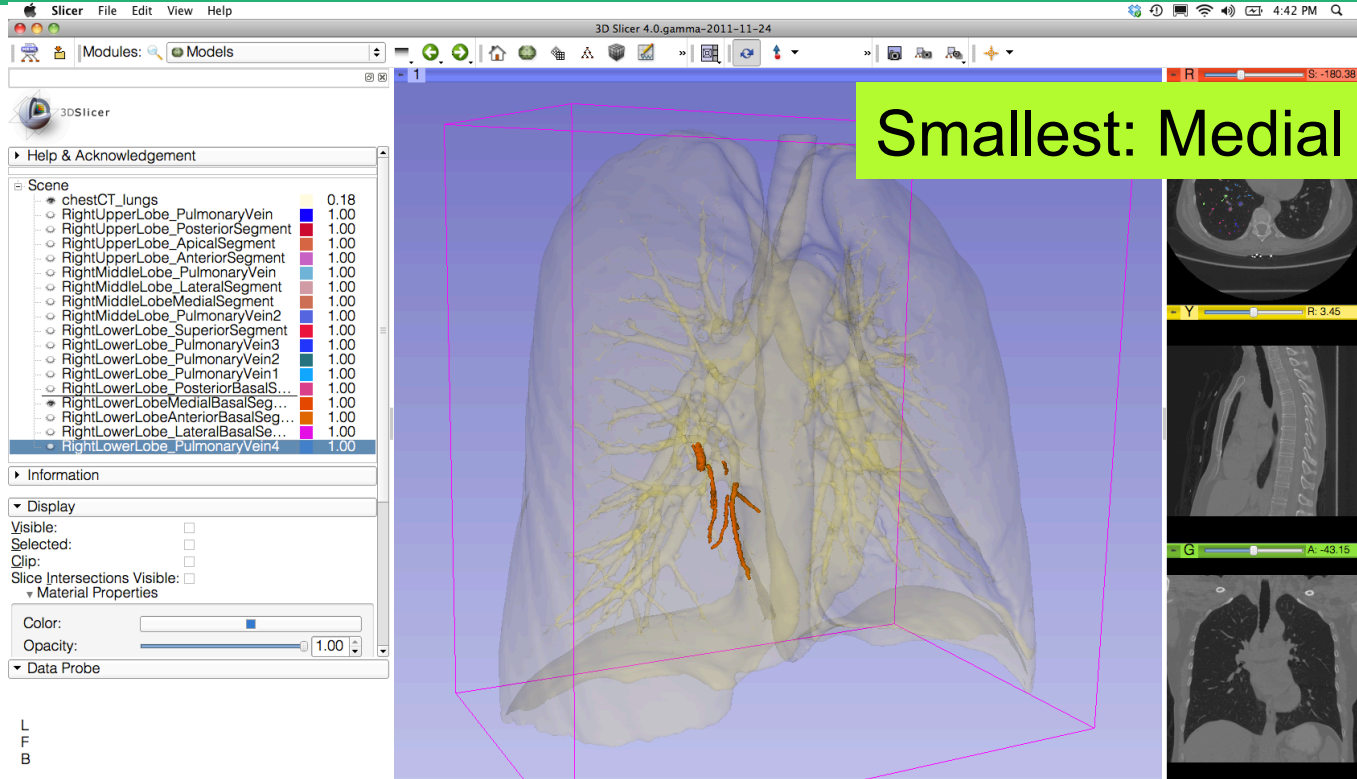
Lung Segments – Question 4

Question 4: Classify the segments of the lower lobe by size



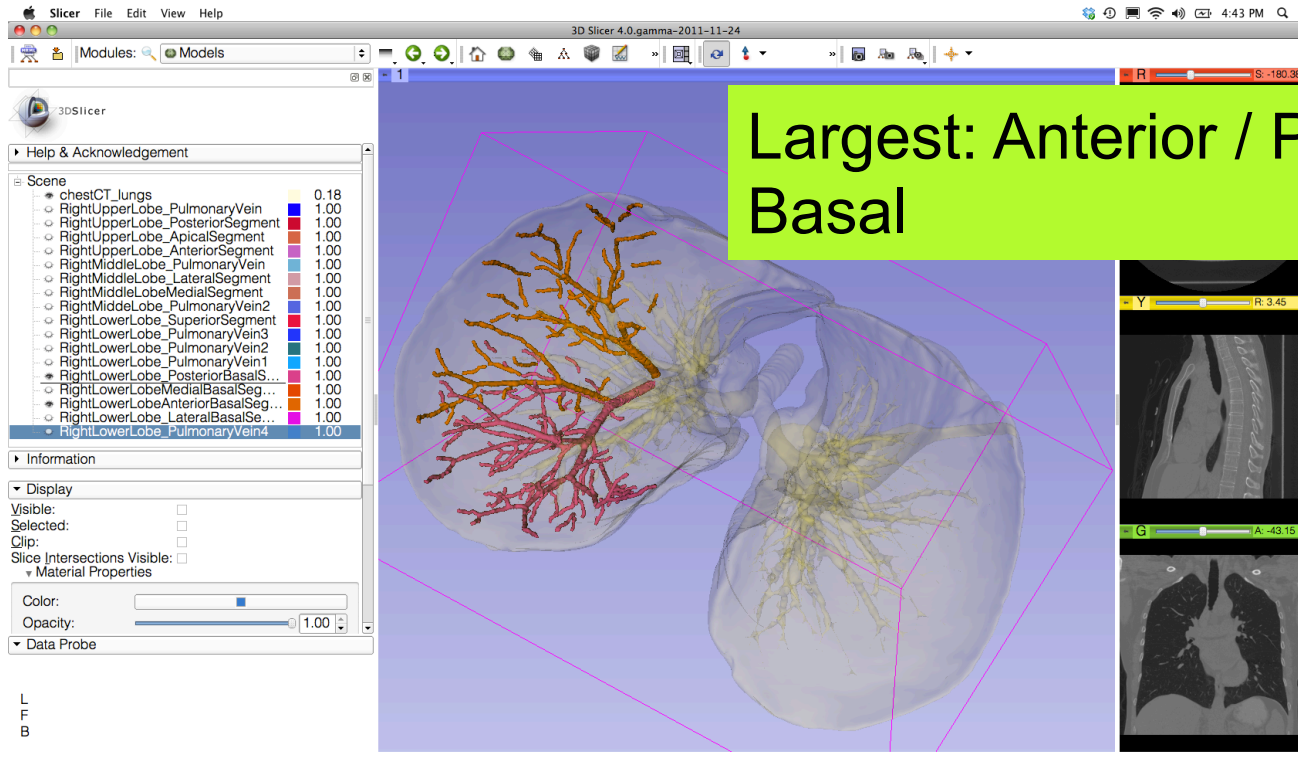


Lung Segments – Question 4



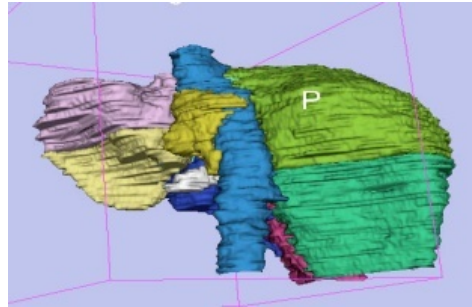
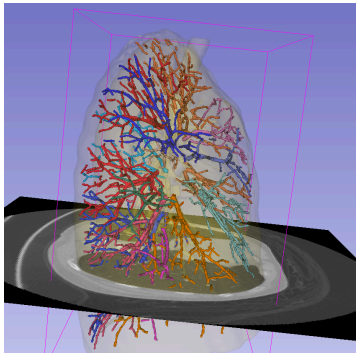
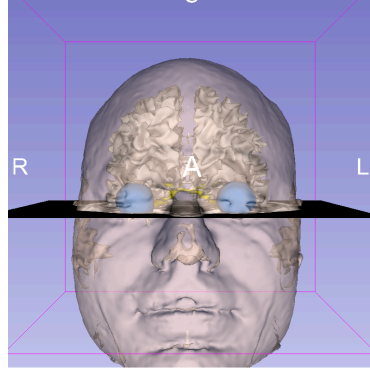
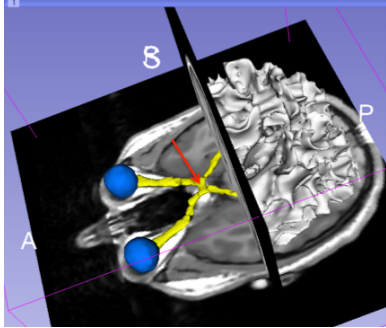


Lung Segments – Question 4





3D Visualization of DICOM images



- Interactive user-interface to load and manipulate greyscale volumes, labelmaps and 3D models.
- User-defined 3D view of the anatomy
- 3D Open-source platform for Linux, Mac and Windows



Acknowledgments



National Alliance for Medical Image Computing (NA-MIC)
(NIH Grant U54EB005149)



Estepar, Washko, Silverman, Ross - Brigham and Women's Hospital.
K25 HL104085, COPDGene 01 HL089897 and U01 HL089856 (lung)

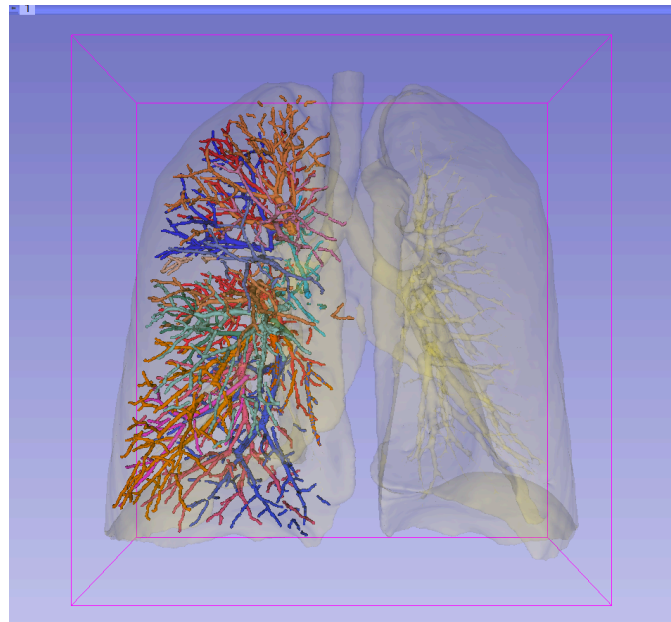


Neuroimage Analysis Center (NAC)
(NIH Grant P41 RR013218)



www.slicer.org

www.na-mic.org



Questions and comments: spujol@bwh.harvard.edu