
Advanced Computer Assistance for Magnetic Resonance-Guided Microwave Thermocoagulation of Liver Tumors

Shigehiro Morikawa, MD, Toshiro Inubushi, PhD, Yoshimasa Kurumi, MD, Shigeyuki Naka, MD, Koichiro Sato, MD, Koichi Demura, MD, Tohru Tani, MD, Hasnine A. Haque, PhD, Junichi Tokuda, BS, Nobuhiko Hata, PhD

Rationale and Objectives. The purpose of this study was to utilize computer assistance effectively for both easy and accurate magnetic resonance (MR) image-guided microwave thermocoagulation therapy of liver tumors.

Materials and Methods. An open configuration MR scanner and a microwave coagulator at 2.45 GHz were used. Navigation software, a 3D Slicer, was customized to combine fluoroscopic MR images and preoperative MR images for the navigation. New functions to display MR temperature maps with simple parameter setting, and to record and display the coagulated areas by multiple microwave ablations in the 3-dimensional space (footprinting), were also introduced into the software. The VGA signal of the computer display was directly transferred to the surgeon's monitor.

Results. The customized software could be used for both accurate image navigation and convenient and easy temperature monitoring. Because repeated punctures and ablations are usually required in this procedure, the footprinting function made targeting of the tumors both easy and accurate and was quite effective in achieving the necessary and sufficient treatment. Furthermore, clear display on the surgeon's monitor, which was obtained by direct transfer of the VGA signal, enabled precise image navigation.

Conclusion. The newly developed computer assistance was quite useful and helpful for this MR-guided procedure.

Key Words. Liver neoplasm; interventional therapy; magnetic resonance (MR) guidance; computer assistance; microwave ablation.

© AUR, 2003

In Japan, microwave thermocoagulation therapy has been applied in open surgery to destruct liver tumors for more than 20 years (1,2). It has also been used in interventional procedures under the guidance of ultrasonography or lapa-

roscopy (3,4). At present, it is established as an effective and reliable minimally invasive therapy for liver tumors. We commenced our clinical studies using an open configuration magnetic resonance (MR) scanner (5) and combined MR image guidance with microwave thermocoagulation therapy of liver tumors using percutaneous puncture (6). Magnetic resonance imaging possesses many advantages for use as image guidance in interventional procedures. It is free from ionizing radiation, has good soft tissue contrast, and has multi-planar, multi-slice capabilities. Microbubbles formed by the ablation did not disturb the visibility of the target by MR images throughout the procedure. In addition to the general advantages for image navigation, MR imaging could monitor tissue temper-

Acad Radiol 2003; 10:1442-1449

¹ From the Molecular Neuroscience Research Center (S.M., T.I.), and the Department of Surgery (Y.K., S.N., K.S., K.D., T.T.), Shiga University of Medical Science, Seta Tsukinowa-cho, Ohtsu, Shiga 520-2192, Japan; GE-Yokogawa Medical Systems, Asahigaoka, Hino, Tokyo, Japan (H.A.H.); and the Graduate School of Information Science and Technology, the University of Tokyo, Bunkyo-ku, Tokyo, Japan (J.T., H.N.). Received May 19, 2003; revision requested August 20; received in revised form August 25, 2003; accepted August 26, 2003. **Address correspondence to S.M.**

© AUR, 2003

doi:10.1016/S1076-6332(03)00508-7

ature changes during ablations noninvasively (7,8). A microwave coagulator at 2.45 GHz did not seriously disturb the MR image acquisition, even during microwave irradiation. A simple notch filter completely prevented any electromagnetic interference in the MR images (6). Thus, the combination of MR images and microwave ablation was quite feasible and synergistic.

This open MR system has mainly been used for neurosurgical procedures (9,10). The MR system, however, presented some difficulties in carrying out procedures for the liver as it was. We have already reported on our development of various new devices and techniques for this procedure during the past 3 years (11,12). A new type of electrode, "firefly," was developed for the clear visualization of the tip position. Originally designed hand piece adaptors for the optical tracking system maintained the line of sight between the light emitting diodes on the hand piece and the detectors above, and also enabled puncture from the side of the patient. A newly prepared MR-compatible endoscopic system was combined with this procedure. Liver tumors just below the diaphragm were safely and effectively treated with transdiaphragmatic puncture under the assistance of a thoracoscope. Among the technical developments for this procedure, the use of customized navigation software, a 3D Slicer, should be most strongly emphasized. Previously, only fluoroscopic MR images, which were acquired every 2 seconds with a T_1 -weighted spoiled gradient echo sequence, were used for image navigation. Clear visualization of the target was the primary issue for the image-guided procedures, but the image quality and contrast of the fluoroscopic MR images were not always satisfactory because of the limited acquisition time. By virtue of the assistance of this innovative software, preoperative 3-dimensional (3D) volume data with high resolution and contrast could be used for the navigation in combination with fluoroscopic MR images. To increase the accuracy, safety, and availability of this procedure, we have been improving the software by adding several new functions. In the present work, our recent progress in computer assistance for this procedure is presented.

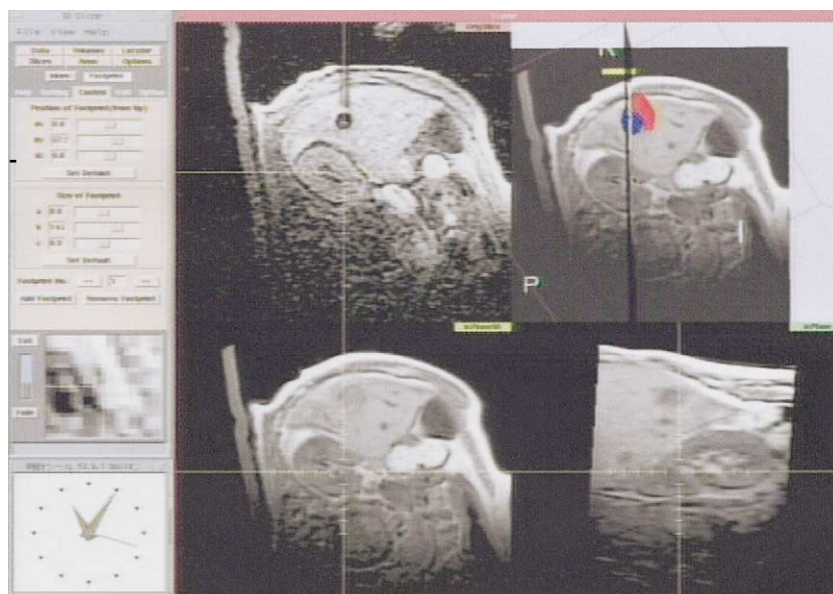
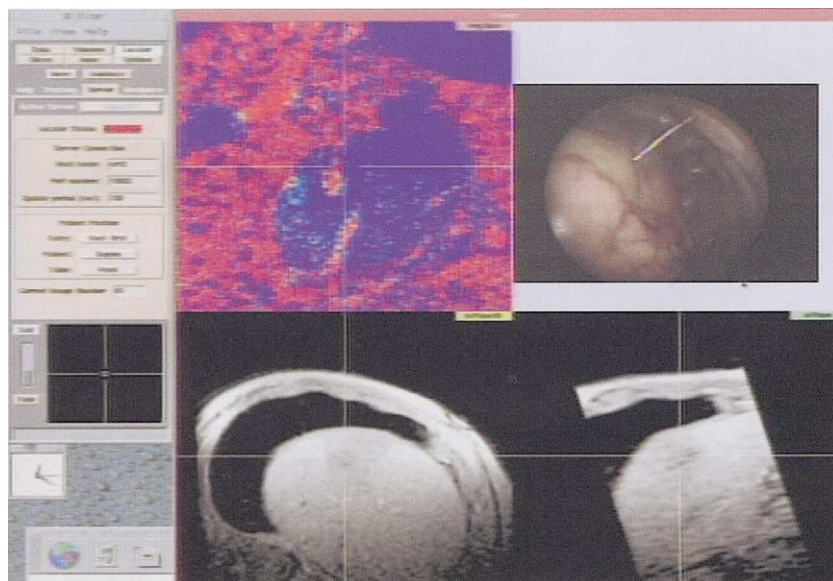
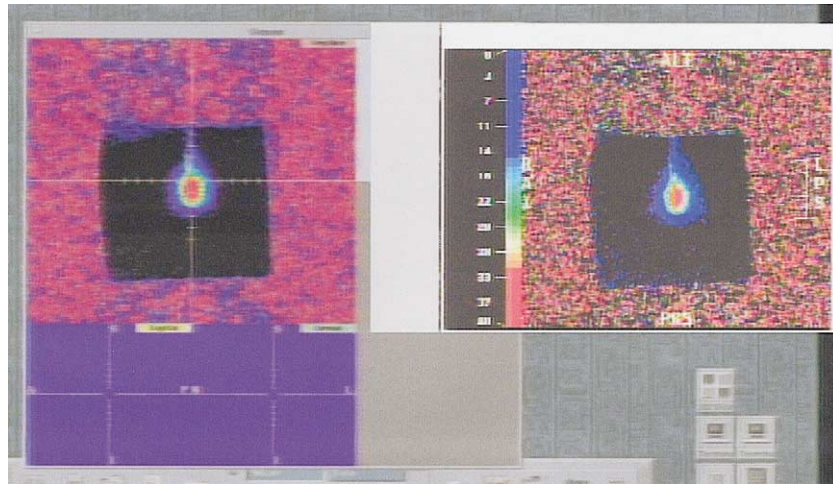
MATERIALS AND METHODS

The ethics committee of Shiga University of Medical Science (Shiga, Japan) approved this study. The procedure and any possible complications related to this type of therapy were explained to each patient, and signed informed consent was obtained from all of the subjects.

From January 2000 to April 2003, 138 cases, consisting of 69 hepatocellular carcinoma and 69 metastatic liver tumors, have undergone this MR-guided microwave thermocoagulation therapy.

Magnetic resonance images were obtained with a double-donut type 0.5 T superconducting SIGNA SP/i system (GE Medical Systems, Milwaukee, WI). In this MR system, an optical tracking system, FlashPoint Model 5000 (Image Guided Technologies Inc, Boulder, CO), was integrated (13). Surgeons could control the MR image planes using a hand piece having three light emitting diodes in combination with our original adaptors for the hand piece (12). Two liquid crystal displays (LCDs) with VGA resolution (640×480) were prepared between the two magnets to show the surgeons the MR images for navigation. Various image sources with a National Television System Committee (NTSC) video signal could be selected with a video switcher of the SIGNA SP/i system and were transferred to the surgeon's LCDs through a penetration panel after up-conversion to VGA signal. Fluoroscopic MR images and temperature maps were acquired using a spoiled gradient echo with 14 ms/3.4 ms (TR/TE), 30×30 cm² field of view and 256×128 resolution, and with 50 ms/13 ms or 33 ms/13 ms (TR/TE), 24×24 cm² field of view and 256×128 resolution, respectively. Temperature changes in individual pixels were calculated by the proton resonance frequency method (7) using a Real Time Image Processing (RTIP) application in the SIGNA SP/i system. The procedure of microwave thermocoagulation of liver tumors has been described previously (6,11,12). In brief, a microwave coagulator, Microtaze (OT-110M, Azwell, Osaka, Japan) was used as the heating device. General anesthesia was primarily used for the procedure (126 of 138 cases). An MR-compatible needle type electrode (length 250 mm \times 1.6 mm diameter, Azwell) was inserted into the tumor through the outer sheath of a percutaneously punctured 14 gauge MR-compatible needle (Daum, Schwerin, Germany). Preliminary observations including ablations during laparotomy showed that a 3-minute ablation at 60 W caused a football shaped coagulation area 20 mm in diameter and 30 mm in length along the electrode (6). Ablations were repeated depending on the size of the tumor.

Navigation software, a 3D Slicer (14,15), which was developed at the Artificial Intelligence Laboratory, Massachusetts Institute of Technology, Cambridge, MA, and Brigham & Women's Hospital, Harvard Medical School, Boston, MA, was installed in an independent SUN Ultra 60 workstation (Sun Microsystems, Santa Clara, CA) and



connected with the MR scanner by a network cable. The output signal of the display from the work station was converted to an NTSC signal by a down-converter (DC 65A, Imagenics, Tokyo, Japan) and was sent to the surgeons' monitors through a video switcher of the SIGNA SP/i system. As reported previously (11,12), a server program that continuously sends acquired fluoroscopic MR images and information on the hand piece position was prepared in the MR system. The 3D Slicer could display a fluoroscopic MR image in combination with two reformatted images (same and perpendicular planes to the fluoroscopic MR image) from preoperative high resolution 3D volume data.

For the present study, an option, which calculated temperature changes by only specifying the baseline image number and then sent the calculated temperature maps to the 3D Slicer continuously, was added to the server program of the MR system. A new function, footprinting, which recorded and displayed football shaped coagulated areas (footprints) 20 mm in diameter and 30 mm in length along the electrode in the 3D space, was introduced to the 3D Slicer. The direction of the electrode was obtained from the information of the FlashPoint system. footprint was placed along the direction of the electrode and its position was manually adjusted along the axis of coordinates determined by the electrode, while referring the fluoroscopic MR images showing the electrode tip. The opacity of the footprints could manually be controlled whenever necessary. Two VGA splitters (AC056A, Black Box, Lawrence, PA) were connected in series to transfer the VGA signal of the computer directly to the surgeons' LCDs by shortcutting the video switcher of the MR system. The VGA splitters also worked as boosters and enabled connection with the long cables between the computer and the surgeons' LCDs.

RESULTS

Temperature Mapping

The temperature map during microwave ablation could be displayed in the 3D Slicer. The results of the temperature calculation of an agar phantom were compared with the RTIP program of the SIGNA SP/i system. The results of the calculation by two applications were combined using a video mixer. As shown in Figure 1, identical results were obtained in both applications. This function was also used in clinical cases (Fig 2). In this case, a temperature increase of more than 30° C was shown in red. In actual clinical cases, the time to set parameters with both the MR scanner and the RTIP programs for temperature monitoring had been a problem when using MR temperature monitoring. For the RTIP program, the information of patient ID, examination, series and image numbers were required to set the baseline image for calculation. Our new application required only the baseline image number and the setting for the temperature calculation could be carried out from the remote workstation independently from the operation on the busy MR system.

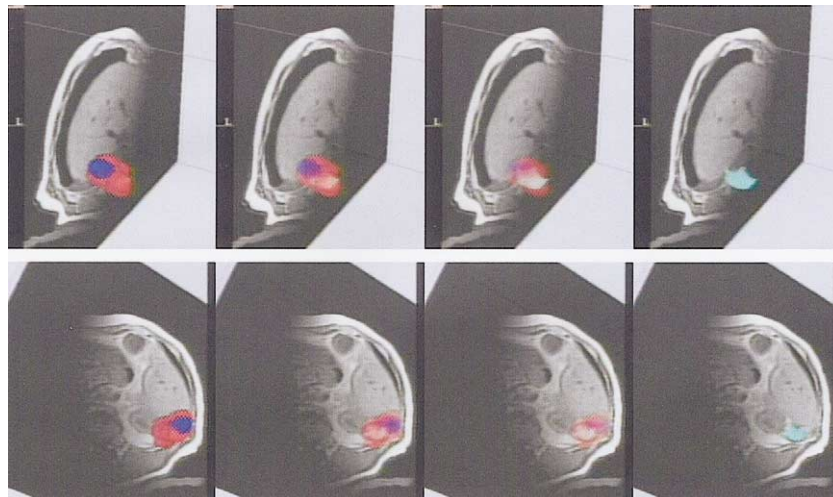
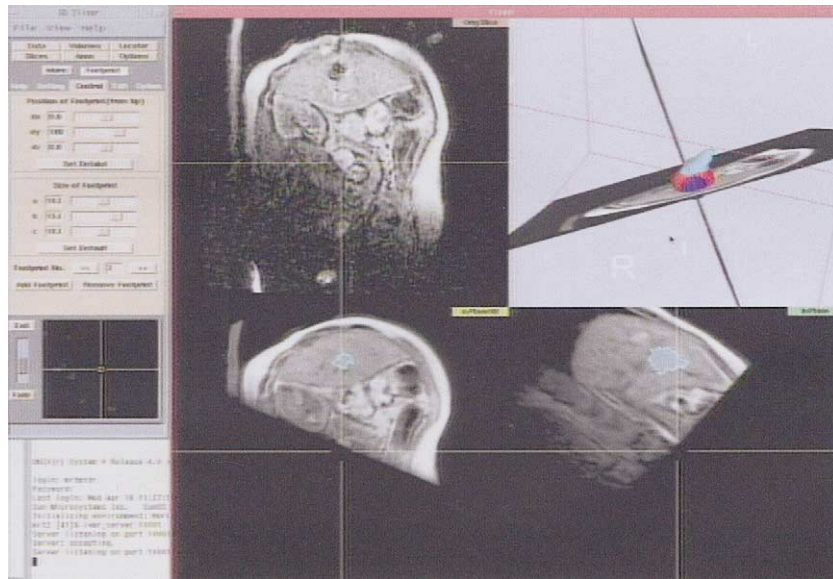
Footprinting

As shown in Figure 3, football-shaped footprints with a size of 20 × 20 × 30 mm³ were placed at the locations of the heating center along the axis of the electrode for each ablation. The previous footprints were shown in red and the current footprint was shown in blue. The use of two colors made it easy to differentiate and to adjust the current footprint position, even after many footprints were accumulated. The current footprint in Figure 3 (in blue), the direction of which was different from that of the previous two (in red), corresponded with the third ablation carried out along with another puncture route. Because

Figure 1. Magnetic resonance temperature maps of an agar phantom during microwave ablation with the 3D Slicer and with the SIGNA SP/i system. The image on the left was calculated by a newly prepared server program on the MR system and was displayed with the 3D Slicer. The image on the right was calculated and was displayed by a RTIP application of the SIGNA SP/i system. The two displays of both applications were combined using a video mixer and were shown concurrently.

Figure 2. Magnetic resonance temperature map during microwave ablation in a clinical case with liver tumor. The temperature map was calculated only by specifying the baseline image number and is displayed with the 3D Slicer in the upper left window. The lower two are reformatted images from preoperative volume data in the same and perpendicular planes to the temperature map. In this case, the lower right image is corresponding with the temperature map. The tumor was punctured through the diaphragm under the assistance of a thoracoscope. The endoscopic image was combined with the 3D Slicer in the upper right portion using a video mixer and was sent to the surgeons' monitors.

Figure 3. Footprinting of the coagulated areas by microwave ablation. The upper left image is a fluoroscopic MR image and the lower two are reformatted images from the preoperative data. The tumor is shown with low signal intensities. In the upper right 3D display, football-shaped footprints with a size of 20 × 20 × 30 mm³ were placed at the locations of the heating center along the axis of the electrode. The previous footprints are shown in red and the current one is shown in blue.



the 3D Slicer originally included a capability of "making model," the tumor area could be shown with a colored 3D volume by tracing the tumor margin in individual slices of the preoperative images. The tumor area and the footprints could be compared from any direction. Their combined display clearly demonstrated already treated and nontreated parts, and specifically indicated to the surgeons which part should be treated next (Fig 4). The targeting of the tumor through one whole procedure, in which multiple punctures were required, became much easier and more accurate to perform. After multiple microwave ablations, the areas of the tumor and the footprints could be carefully compared by controlling the opacity of the footprints from multiple directions (Fig 5). This function was helpful to achieve the necessary and sufficient treatment of the tumors.

Display of VGA Signal

The surgeons' LCDs between the magnets only accepted a VGA signal with 640×480 resolution. Therefore, the resolution of the computer display had to be reduced to 640×480 to transfer the signal to the surgeon's monitor directly. Although the resolution of the display was limited, the display with direct signal transfer through the VGA splitters on the same monitor was much clearer and brighter than that with down-conversion to the NTSC signal and through the original configuration for display of the SIGNA SP/i system (Fig 6). Down-conversion and up-conversion of the signal obviously made the computer display blurry and dark.

DISCUSSION

Magnetic resonance temperature monitoring is undoubtedly a potential tool for the real-time evaluation of the therapeutic effects of thermal ablation. One major reason we combined MR guidance and microwave ablation was the availability of MR temperature monitoring

during microwave ablation (16). Actually, good and reasonable results could be obtained with phantoms or excised tissues. In clinical cases with liver tumors, however, many difficulties existed when using MR temperature monitoring. Because temperature changes were calculated by only slight differences in the water proton resonance frequency from the baseline condition, this technique was highly susceptible to the movement of the liver. To apply MR temperature monitoring to the liver, respiratory suspension or respiratory triggering (17) was required to eliminate the motion artifacts of the liver. Movements of the surgeons and surgical instruments also affected the static magnetic field around the target and, as a result, errors in calculation could be induced. From the technical aspect with this MR system, the complicated process and required time for the parameter setting of temperature monitoring were also problems when applying this technique to clinical cases. The improvement of easy and quick parameter setting with our new application was an important step in using temperature monitoring as a useful clinical tool for the evaluation of the therapeutic effects. Further improvements on the MR temperature monitoring are now in progress.

From the viewpoint of electromagnetic interference in the MR images, microwave ablation at 2.45 GHz was much more favorable than radiofrequency ablation at 500 KHz. With radiofrequency ablation, a switching circuit for time sharing was required to reduce the noise in the MR images (18). One disadvantage of microwave ablation, however, was the relatively small size of coagulation with one ablation compared with that of radiofrequency ablation. Therefore, repeated punctures and ablations were usually required in microwave thermocoagulation therapy. The visualization of the target was maintained throughout the procedure and was not disturbed by microbubbles formed by the ablations, but it was difficult to differentiate between already treated and nontreated areas with plain MR images. For their differentiation, enhanced MR

Figure 4. Combination of the 3D information of the tumor area and footprints is shown. The tumor area is shown in light blue 3D volume, and the ablated areas are shown with red and blue footprints. The combination of the tumor volume and the footprints clearly visualized the already treated and nontreated parts.

Figure 5. Comparison of the 3D tumor area and the footprints. The tumor area is shown in light blue and the footprints are shown in red and blue. The opacity of the footprints could be controlled and the areas of the tumor and footprints could be compared carefully from multiple directions.

Figure 6. Displays of the 3D Slicer on the surgeons' monitor with different signal transfer systems. The upper one is a display with the original configuration of the SIGNA SP/i system through the NTSC signal. The lower one is a display with direct transfer of the VGA signal through two VGA splitters. The resolution of the computer display was reduced to 640×480 . The two pictures of the same LCD were taken under the same conditions.

studies using an MR contrast media were generally required. The contrast media could not be used frequently within one procedure, and an enhanced MR study was usually performed only one time at the end of the procedure for the evaluation of the therapeutic effects. In addition, surgeons were required to remember which part had already been treated and which part should be treated next. It was not easy for the surgeons to perform the necessary and sufficient ablations for the target based only on their retentive memory. The footprinting function of the 3D Slicer could release the surgeons from such stress and concerns. Three-dimensional information concerning the tumor area and treated volume was a unique feature of this navigation software and was quite helpful for the procedure. Using this function, both effective and reliable treatment could be realized even if multiple punctures and ablations were required. At present, the sizes and shapes of footprints are fixed, although they might be influenced by the blood flow or tissue types. When more usable and reliable MR temperature maps for clinical cases are realized in the near future, the shape and size of footprints will be determined by the results of temperature maps.

The interventional microwave thermocoagulation therapy has mainly been carried out under the guidance of ultrasonography. Actually, ultrasonography is an easy, handy, and cost-effective instrument, but it has some limitations. The ribs and air space disturb the visibility of ultrasonography and the possible puncture routes are limited. It is sometimes difficult to detect the lesions in the deep parts of the liver. Microbubbles formed by the ablations also disturb the visibility and repeated ablations are difficult. The use of MR guidance should be especially beneficial for cases in which microwave ablation is difficult to perform under the guidance of ultrasonography. Such cases are now selectively transferred to our hospital from other clinics. In addition, the accurate image navigation by an external computer and the monitoring of the treatment by the footprinting function and MR temperature maps are the big advantages of the MR guidance. We have already reported clinical results of this procedure after short periods (6). A clinical follow-up study is now in preparation and the results will show the value of this MR-guided procedure. Because the footprinting function is our recent development, a little more time will be required for the evaluation of its effect on the clinical outcome.

The surgeon's LCD was a specific problem for this double-donut type open MR system. Because the LCDs had to be located between the two magnets to display

various images for the surgeons, they were bared under a much stronger magnetic field than those with a hamburger type open MR system, in which the LCDs were located outside of the magnets. The size of the LCD was also limited by the space between the magnets. These might be the reasons why the old LCDs were left without upgrading. For interactive image navigation as in this procedure, especially with computer assistance, a clear and bright LCD with high resolution is an essential requirement. Because the improvement of the hardware was difficult to accomplish by ourselves, the path of the signal transfer to the LCD was modified. As a result, much clearer and brighter displays on the same LCDs could be attained. Once we experienced a very good display, it was difficult to revert back to the previous situation. The 640×480 resolution, however, was too small to operate the 3D Slicer with multiple windows or to display other image sources such as endoscopic images. At present, we cannot shift completely to the new display system. The two display systems are therefore chosen on a case-by-case basis. Improvement of the existing hardware is eagerly awaited.

In conclusion, we have added several new features to our navigation software for interactive image navigation for MR-guided microwave ablation of liver tumors and have improved the signal transfer of the computer display to the surgeons' LCDs. These technical developments in computer assistance have substantially increased the safety, accuracy, and reliability of this procedure.

ACKNOWLEDGMENT

The authors are deeply indebted to Ferenc A. Jolesz, MD, and Ron Kikinis, MD (Brigham & Women's Hospital, Boston MA) for donating the 3D Slicer software.

REFERENCES

1. Tabuse K. A new operative procedure of hepatic surgery using a microwave tissue coagulator. *Arch Jpn Chir* 1979; 48:160-172.
2. Hamazoe R, Hirooka Y, Ohtani S, et al. Intraoperative tissue coagulation as treatment for patients with nonresectable hepatocellular carcinoma. *Cancer* 1995; 75:794-800.
3. Seki T, Wakabayashi M, Nakagawa T, et al. Ultrasonically guided percutaneous microwave coagulation therapy for small hepatocellular carcinoma. *Cancer* 1994; 74:817-825.
4. Ido K, Isoda N, Kawamoto C, et al. Laparoscopic microwave coagulation for solitary hepatocellular carcinoma performed under laparoscopic ultrasonography. *Gastrointest Endosc* 1997; 45:415-420.
5. Schenck JF, Jolesz FA, Roemer PB, et al. Superconducting open-configuration MR imaging system for image-guided therapy. *Radiology* 1995; 195:805-814.
6. Morikawa S, Inubushi T, Kurumi Y, et al. MR-Guided microwave ther-

- mocoagulation therapy of liver tumors: initial clinical experiences using a 0.5 T open MR system. *J Magn Reson Imaging* 2002; 16:576–583.
7. De Poorter J, De Wagter C, De Deene Y, et al. Noninvasive MRI thermometry with the proton resonance frequency (PRF) method: in vivo results in human muscle. *Magn Reson Med* 1995; 33:74–81.
 8. Kahn T, Harth T, Kiwit JCW, et al. In vivo MRI thermometry using phase-sensitive sequence: preliminary experience during MRI-guided laser-induced interstitial thermotherapy of brain tumors. *J Magn Reson Imaging* 1998; 8:160–164.
 9. Black PM, Alexander E III, Martin C, et al. Craniotomy for tumor treatment in an intraoperative magnetic resonance imaging unit. *Neurosurgery* 1999; 45:423–431.
 10. Pergolizzi RS Jr, Nabavi A, Schwartz RB, et al. Intra-operative MR guidance during trans-sphenoidal pituitary resection: preliminary results. *J Magn Reson Imaging* 2001; 13:136–141.
 11. Morikawa S, Inubushi T, Kuarumi Y, et al. Technical developments for MR-guided microwave thermocoagulation therapy of liver tumors. Proceedings of the Medical Image Computing and Computer-Assisted Intervention, Tokyo: Springer, 2002 Lecture Notes I in Computer Science 2489: 52–59.
 12. Morikawa S, Inubushi T, Kurumi Y, et al. New assistive devices for MR-guided microwave thermocoagulation of liver tumors. *Acad Radiol* 2003; 10:180–188.
 13. Silverman SG, Collick BD, Figueira MR, et al. Interactive MR-guided biopsy in an open-configuration MR imaging system. *Radiology* 1995; 197:175–181.
 14. Jolesz FA, Nabavi A, Kikinis R. Integration of interventional MRI with computer-assisted surgery. *J Magn Reson Imaging* 2001; 13:69–77.
 15. Gering DT, Nabavi A, Kikinis R, et al. An integrated visualization system for surgical planning and guidance using image fusion and an open MR. *J Magn Reson Imaging* 2001; 13:967–975.
 16. Morikawa S, Inubushi T, Kurumi Y, et al. Feasibility of microwave ablation for MR-guided interstitial thermal therapy: an experimental study using 2T MR system. *Jpn J Magn Reson Med* 2001; 21:79–84.
 17. Morikawa S, Inubushi T, Kurumi Y, et al. Feasibility of simple respiratory triggering in MR-guided interventional procedures for liver tumors under general anesthesia. Proceedings of the International Society for Magnetic Resonance in Medicine. Tenth Scientific Meeting and Exhibition, Honolulu, HI. May 20–24, 2002. Berkeley, CA: ISMRM; 2002, 10: 22–40
 18. Zhang Q, Chung YC, Lewin JS, Duerk JL. A method for simultaneous RF ablation and MRI. *J Magn Reson Imaging* 1998; 8:110–114.